

Journal

CALIFORNIA DENTAL ASSOCIATION

June 2015

Dental Identification

Age Estimation

Bite-Mark and Pattern
Injury Analysis



**Forensic
Odontology**

Duane Spencer, DDS



**You are not a
market segment.**



You are also not a sales goal or a policy number. You are a dentist. One who deserves superior protection, exceptional service and a fair price. That's something we understand at TDIC. Case in point, the Optimum Bundle.

TDIC Optimum Bundle

Professional Liability
Commercial Property
Workers' Compensation

Discounts apply to individual policies and are not cumulative. To obtain the Professional Liability premium five (5) percent, two-year discount, California dentists must complete the current TDIC Risk Management seminar. Call 800.733.0634 for current deadlines and seminar details.

Good

10% discount on Professional Liability when combined with Workers' Compensation

Better

10% discount on both Professional Liability + Commercial Property when combined

Optimum

20% discount on Professional Liability

10% discount on Commercial Property

5% discount on Workers' Compensation

Bonus

Additional 5% discount on Professional Liability when you take the current TDIC Risk Management seminar.

Protecting dentists. It's all we do.®

800.733.0633 | tdicsolutions.com | CA Insurance Lic. #0652783

DEPARTMENTS

- 281 The Associate Editor/*To Delete or Not to Delete, That Is the Question*
- 283 Letters to the Editor
- 285 Impressions
- 333 RM Matters/*Report Employee Injuries Immediately*
- 337 Regulatory Compliance/*Uses and Disclosures of Patient Health Information: Part II*
- 342 Tech Trends



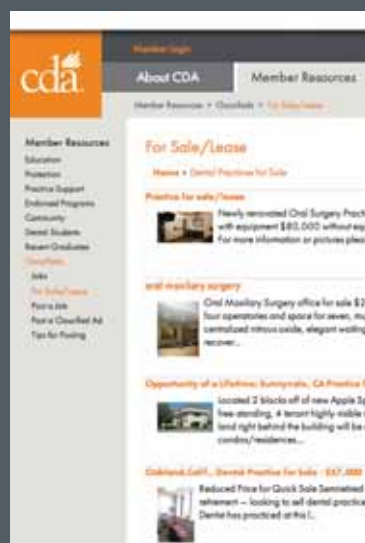FEATURES

- 292 Forensic Odontology
An introduction to the issue.
Duane Spencer, DDS
- 295 Overview of Forensic Odontology
This article provides an overview of the field of forensic odontology and suggests ways to become involved.
Roger D. Metcalf, DDS, JD, and Janice Klim-Lemann, DDS
- 303 Atypical Forensic Dental Identifications
Forensic dental identification is accomplished by comparing radiographs of the decedent's teeth with the dental radiographs obtained from the dentist of the suspected victim. Unfortunately, antemortem dental radiographs are not always available.
Anthony R. Cardoza, DDS, and James D. Wood, DDS
- 309 Bite-Mark and Pattern Injury Analysis: A Brief Status Overview
This article discusses some issues that persist in forensic circles and the difficulties surrounding the field of bite-mark analysis that inherently must employ human subjectivity in its execution of duty.
Gregory S. Golden, DDS, DABFO
- 315 Forensic Dental Age Estimation: An Overview
This article reviews the principles, methodology and commonly used techniques in forensic age estimation cases.
James M. Lewis, DMD, DABFO, and David R. Senn, DDS, DABFO
- 321 The Forensic Dentist: An Overview of Expert Roles in Animal Bite-Mark Investigations
With increasing incidence of human/animal confrontation and the potential for injury or even death, dentists who choose to work in the forensic sciences may be called upon to utilize their skills and training to render opinions in criminal and civil cases.
Kenneth Cohn, DDS, MAGD, DABFO, and Ron Berman, BA, CFE, DABFE

CDA Classifieds.

Free postings.

Priceless results.



CDA classifieds work harder to bring you results. Selling a practice or a piece of equipment? Now you can include photos to help buyers see the potential.

And if you're hiring, candidates anywhere can apply right from the site. Looking for a job? You can post that, too. And the best part—it's **free** to all CDA members.

All of these features are designed to help you get the results you need, faster than ever. Check it out for yourself at cda.org/classifieds.



published by the
California
Dental Association
1201 K St., 14th Floor
Sacramento, CA 95814
800.232.7645
cda.org

CDA Officers

Walter G. Weber, DDS
PRESIDENT
president@cda.org

Kenneth G. Wallis, DDS
PRESIDENT-ELECT
presidentelect@cda.org

Clelan G. Ehrler, DDS
VICE PRESIDENT
vicepresident@cda.org

Natasha A. Lee, DDS
SECRETARY
secretary@cda.org

Kevin M. Keating, DDS, MS
TREASURER
treasurer@cda.org

Craig S. Yarborough, DDS,
MBA
SPEAKER OF THE HOUSE
speaker@cda.org

James D. Stephens, DDS
IMMEDIATE PAST PRESIDENT
pastpresident@cda.org

Management

Peter A. DuBois
EXECUTIVE DIRECTOR

Jennifer George
CHIEF MARKETING OFFICER

Cathy Mudge
VICE PRESIDENT,
COMMUNITY AFFAIRS

Alicia Malaby
COMMUNICATIONS
DIRECTOR

Journal

CALIFORNIA DENTAL ASSOCIATION

Volume 43, Number 6
June 2015

Editorial

Kerry K. Carney, DDS, CDE
EDITOR-IN-CHIEF
Kerry.Carney@cda.org

Ruchi K. Sahota, DDS, CDE
ASSOCIATE EDITOR

Brian K. Shue, DDS, CDE
ASSOCIATE EDITOR

Duane Spencer, DDS
GUEST EDITOR

Andrea LaMattina
PUBLICATIONS SPECIALIST

Blake Ellington
TECH TRENDS EDITOR

Courtney Grant
COMMUNICATIONS
SPECIALIST

Jack F. Conley, DDS
EDITOR EMERITUS

Robert E. Horseman, DDS
HUMORIST EMERITUS

Production

Val B. Mina
SENIOR GRAPHIC DESIGNER

Randi Taylor
SENIOR GRAPHIC DESIGNER

Upcoming Topics

July/Geriatrics I

August/Geriatrics II

September/Radiology

Advertising

Doug Brown
ADVERTISING SALES
Doug.Brown@cda.org
916.554.7312

Tiffany Carlson
ADVERTISING SALES
Tiffany.Carlson@cda.org
916.554.5304

Permission and Reprints

Andrea LaMattina
PUBLICATIONS SPECIALIST
Andrea.LaMattina@cda.org
916.554.5950

Manuscript Submissions

www.editorialmanager.com/jcaldentassoc

Letters to the Editor

www.editorialmanager.com/jcaldentassoc

Subscriptions

Subscriptions are available only to active members of the Association. The subscription rate is \$18 and is included in membership dues. Nonmembers can view the publication online at cda.org/journal.

Manage your subscription online: go to cda.org, log in and update any changes to your mailing information. Email questions or other changes to membership@cda.org.

Stay Connected cda.org/journal



Go Digital cda.org/apps



Look for this symbol, noting additional video content in the e-pub version of the *Journal*.

Journal of the California Dental Association (ISSN 1043-2256) is published monthly by the California Dental Association, 1201 K St., 14th Floor, Sacramento, CA 95814, 916.554.5950. Periodicals postage paid at Sacramento, Calif. Postmaster: Send address changes to *Journal of the California Dental Association*, P.O. Box 13749, Sacramento, CA 95853.

The California Dental Association holds the copyright for all articles and artwork published herein. The *Journal of the California Dental Association* is published under the supervision of CDA's editorial staff. Neither the editorial staff, the editor, nor the association are responsible for any expression of opinion or statement of fact, all of which are published solely on the authority of the author whose name is indicated. The association reserves the right to illustrate, reduce, revise or reject any manuscript submitted. Articles are considered for publication on condition that they are contributed solely to the *Journal*.

Copyright 2015 by the California Dental Association. All rights reserved.



To Delete or Not to Delete, That Is the Question

Brian Shue, DDS, CDE

As dentists — the No. 1 best job in 2015 according to the annual rankings by *U.S. News and World Report* (apparently, the No. 2 best job is being Apple CEO Tim Cook) — we have many pressing duties besides our daily schedules that demand our attention throughout the day: reading emails, deleting emails, reading emails, etc.

And so far in the 21st century, email still remains the most common form of business communication. In 2014, 196.3 billion emails were sent and received every day, and digging deeper, each business user will receive on average 88 emails per day and send 38 emails per day in 2015.¹ Sending 38 emails per day doesn't seem like very many, but over a four-year period that would amount to 55,480 emails.

Some emails can be quite interesting. Here are some that made it to my inbox:

From the sick. “Dear,” one email started, “Walk in the path of righteousness and goodness and mercy shall forever follow you all the days of your life.” The sender then tells me she has been on her deathbed for five years and says, “Now I believe that my time has come to join my ancestors in heaven. Through divine revelation, I got your email address from the Internet. I have \$8,000,000 deposited in a safe location.” This conjured up the image of a sender barely mustering enough energy to search for my email address, press the “send” button and then lapse back into unconsciousness.

From patriotic men and women who defend our freedoms. No, not Fox News anchors, I mean soldiers. One U.S. Army captain has two military trunk boxes of booty hidden in the U.K. that he took from Iraq. Another soldier in Afghanistan has an undisclosed amount of Benjamins hidden in a tunnel and he needs help in moving it to a more secure location.



On average, one out of eight emails you will receive each day this year can be categorized as spam.

You surely receive unsolicited commercial emails like these, also known as spam or junk emails, interspersed with all of your important emails. On average, one out of eight emails you will receive each day this year can be categorized as spam.² And that is not even counting the staggering amounts that technology and anti-all-that-is-bad programs battle to keep away from ever reaching our inboxes like yesterday's electronic trash.

Can spam be banned? Can the image of singing Vikings gathered in an English diner ever be forgotten?³ No. The U.S. Department of Justice defends the existence of spam, stating, “Much of it has a legitimate business purpose.” But much of it does not, including email scams like those mentioned above.

Here are the most commonly reported scams in 2014, according to the Federal Trade Commission (FTC): IRS phone calls and/or emails, the Prize Patrol from Publisher's Clearinghouse, technical support warning your computer needs immediate servicing and/or malware that needs to be removed and the Nigerian scam involving the FBI.⁴

Notice how prevalent computer technology is involved in these criminal scams. And consider the Nigerian scam, named after the country from where this type of fraud first emerged. It is an advanced fee scheme from a trustworthy “representative” who will give you a cut of millions of dollars in return for

helping the sender access riches locked away. The FTC says these scams are “characterized by convincing sob stories” and “unfailing polite language” in their attempt to get your personal information and/or bank account number.

In addition to service members and those on their last breath, I have also received offers from executives from African oil fields and foreign bank officials, including one from the “Tamale Branch of the Bank of Ghana.” In exchange for my help, I have seen emails offer as low as 20 percent of the windfall to as high as 40 percent. One graciously offered to let me pick my own percentage. If I cooperate, another email reassures “it is not illegal in any way nor will either of us be breaking any laws.” Another sender asks, “Can you honestly help me from your heart?” *Sure, that's why I wanted to be a dentist, to help people.* “Can I completely trust you?” *Of course you can, dentists are Gallup poll's third most-ethical profession.*

But no one falls for these schemes, right? You'd be surprised. Victims have actually traveled to other countries to complete these transactions, sometimes even shown trunks of fake cash, as they fall deeper into trouble. “According to State Department reports, people who have responded to these emails have been beaten, subjected to threats and extortion, and in some cases, murdered,” says the FTC.

Enter the Internet Crime Complaint Center (IC3), a central processing system whose mission is to “receive, develop and refer criminal complaints regarding the rapidly expanding arena of cyber crime.” The IC3, comprised of the FBI and the National White Collar Crime Center, partners with the proper law enforcement level of authority. “Internet crime is defined as any illegal activity involving one or more components of the Internet such as websites, chat rooms and/or email,” says IC3. “Internet crime involves the use of the Internet to communicate false or fraudulent representations to consumers.”

Follow these common-sense recommendations from the Department of Justice and the FTC to minimize spam and to reduce your chances of becoming a victim of an email scam:⁵

- Filter spam. Use the features on your email applications or mail services to prevent as much as possible.
- Don't trust unsolicited email. Don't open attachments, don't click on links from unsolicited email, don't buy anything and don't respond.
- Approach email attachments and links, even from those you know, with caution.
- Use antivirus software and personal firewalls and keep them up to date.
- Configure your email client for security by changing email viewing as text only.
- Keep your email address as private as possible.
- Have a primary and secondary email address and use one for people you know and one for all other purposes.
- File an email scam complaint at the IC3 website www.ic3.gov/default.aspx.
- Forward unwanted spam to the FTC at spam@uce.gov.

So the next time you get an email from a sender, more direct than David Lee Roth backstage after a Van Halen concert, with a message like this: “I have \$36.6 million in business to acquaint with you. Contact me,” you know what to do. And remember, it may not be *you* who falls for these fraudulent emails, but it could very well be someone you know. ■

REFERENCES

1. Radicati S. Email Statistics Report, 2014-2018. www.radicati.com/wp/wp-content/uploads/2014/01/Email-Statistics-Report-2014-2018-Executive-Summary.pdf. April 14, 2014.
2. Ibid.
3. 1970 episode of Monty Python's *Flying Circus*.
4. Kando-Pineda C. The Grate Pretenders. www.onguardonline.gov/blog/grate-pretenders. March 2, 2015.
5. Department of Justice. Recognizing and Avoiding Email Scams. www.us-cert.gov/sites/default/files/publications/emailscams_0905.pdf. Accessed March 13, 2015.

Brian K. Shue, DDS, is the dental director of a federally qualified health center. He is a certified dental editor, the San Diego County Dental Society editor and is a fellow of the American College of Dentists and the Pierre Fauchard Academy.

Read this issue on your iPad.*



*Also available for iPhone, Android or Kindle Fire. Check it out at cda.org/apps

cda

What Is Affordable?

Lambert Stumpel, DDS, writes in his March 2015 *Journal* article, “A Simple, Safe and Affordable Cast-Based Guided Implant Placement System,” that in San Francisco where he practices, a cone beam CT (CBCT) fee is \$400 and an intraoral scan is \$50. Dr. Stumpel opines that this CBCT cost is not financially feasible for a dentist placing one or two implants.

The University of the Pacific, Arthur A. Dugoni School of Dentistry fee is \$258 for a narrow field Accutomo CBCT of three teeth including a board certified radiologist’s report. Its low radiation dosage of 20 microsieverts, high-quality resolution and anatomical accuracy is invaluable for implants being placed in close proximity to vital structures such as the inferior alveolar nerve canal or sinuses.

Private dental X-ray labs in San Francisco charge \$200 for a focused field CBCT of one to three teeth.

Patient safety is priceless when placing implants. Why should not this choice of superior technology be included with informed consent? We don’t X-ray a patient’s pocketbook. We should nevertheless provide reasonable choices so the patient can decide what is affordable and in the patient’s best interest.

EDWIN ZINMAN, DDS, JD
San Francisco, Calif.

Dr. Stumpel responds

I would like to thank Dr. Zinman for commenting on my March 2015 *Journal* article, “A Simple, Safe and Affordable Cast-Based Guided Implant Placement System.”

There is no discussion that when needed, CBCT is wonderful technology that should be used based on the ALARA principle, acronym for as low as reasonably achievable. Only if there is

patient benefit should ionizing radiation be used. In addition, most are well aware that health care cost in this country is the highest in the world. We should be sensitive to the fact that controlling cost is in our patient’s interest. The described guide allows very precise implant placement, while controlling cost.

The article was comparing a cast-based method to fabricate a fully restrictive surgical guide to the computer-aided design/computer-aided manufacturing (CAD/CAM) produced surgical guides. To produce a CAD/CAM guide one needs a full arch in the CBCT data set. A full arch is needed to accurately match the stereolithography (STL) file of the teeth. Partial datasets will introduce massive errors between planned and actual implant position.

The information from a small field CBCT can easily be used when fabricating a 3D Click Guide, and when needed that is what we do. To fabricate a CAD/CAM guide one would need a full arch.

The cost as described in my article is \$450 for the data sets required.

LAMBERT J. STUMPEL, DDS
San Francisco, Calif.

The Sum of Its Parts

I was interested in reading the editorial on holistic dentistry in the March 2015 issue of the *Journal*. The term “holistic” simply means that the whole is greater than the sum of its parts. A dentist who takes a holistic approach to dentistry sees his or her patient as a whole person with a unique life experience. We are not just repairing teeth; we are helping our patients become healthier.

We compartmentalize our education into departments such as operative, endodontics, periodontics,



etc. Our patients are not divided up that way. They are whole and complete with body, mind and spirit.

Neither Hal Huggins, DDS, MS, or any of the other dentists were “holistic” dentists. Dr. Huggins had a protocol that he called “balancing body chemistry.” If they have a particular technique or protocol, by definition it cannot be holistic.

Most of the diseases we treat are preventable. Preventing dental disease is more desirable than allowing it to happen and then repairing the damage afterward.

If we want to really help our patients become healthier, we have to move beyond simply presenting treatment plans and repairing teeth. We all know that there are dentists who have excellent behavioral and communication skills that serve their patients in an exceptional way. The Pankey Institute is named for one of these dentists, L.D. Pankey, DDS.

The editorial mentions a dentist named Weston Price. Dr. Price traveled with his wife to primitive areas of the world to study the effects of nutrition

on people's health. The outcome was a monumental book called *Nutrition and Physical Degeneration*. His research took place before the advent of antibiotics, when dental infections could be more life threatening.

A holistic approach is a systems approach — nothing is left out. We look at the entire stomatognathic system.

The three main causes of dental disease are caries, periodontal disease and malocclusion. These are all interrelated and we do not treat them separately.

In the course of doing comprehensive care, some of our patients were reporting that other health problems had cleared up as a result of their lifestyle

changes. People reported that their chronic headaches had cleared up and others reported that they no longer had leg cramps or seasonal allergies.

I do not like to hear our profession referred to as the dental “industry.” We are not a commercial enterprise and we are not in competition with our fellow dentists or our patients. As professionals, we share our knowledge freely.

Over the years, we have grown from being tooth pullers to dental repairmen.

By taking a broader view of our profession, we can expand our vision to becoming true health professionals.

PHILIP HORDINER, DDS
Los Altos, Calif.

The Journal welcomes letters

We reserve the right to edit all communications. Letters should discuss an item published in the Journal within the past two months or matters of general interest to our readership. Letters must be no more than 500 words and cite no more than five references. No illustrations will be accepted. Letters should be submitted at editorialmanager.com/jcaldentassoc. By sending the letter, the author certifies that neither the letter nor one with substantially similar content under the writer's authorship has been published or is being considered for publication elsewhere, and the author acknowledges and agrees that the letter and all rights with regard to the letter become the property of CDA.

CDA Journal Readers! Lock in this price for 2015

Reg. \$75

\$49
Per Unit

kortzTM
SOLID ZIRCONIA



Hatzakortzian
Dental Laboratory, Inc.

888-345-0173

Call for your Free No Obligation Starter's Kit
Takes 2 Minutes to Setup an Account. Call for Details



I, IT, THEY,
WE...

A Grammar of Ethics

David W. Chambers, EdM, MBA, PhD

Parsing logical sentences and distinguishing one ethical philosopher from another probably compete for last place among the exciting things to do on a Sunday afternoon, right up there with untangling the wires for the stereo system and alphabetizing the canned soups in your pantry. There is a reason — after we have done it, no one can tell the difference.

Here is the connection between grammar and ethics. First-person ethics is an academic exercise. Third-person ethics is gossip. Speaking about ethics in the second person almost never happens. Some things we say about ethics never get out of the “I” voice. Some sentences point fingers at “they” or “it.” After we have done it, no one can tell the difference. The precious cases begin, “We ...”

It is very hard to think of an example of ethics that is entirely private. Almost per definition, to count as good or bad, what we do has to affect others. So should the solution. There is a danger in mistaking a one-party solution to a two-party problem for a sound, two-party ethical resolution.

The real annoyance is third-person ethics. “*He* should be doing ...” “Did you hear how *they* are overcharging, misrepresenting, underdiagnosing, patient stealing and all the rest? Makes one sick.” There are three parties in these third-party grumblings: Dr. Righteous, the friend of Dr. Righteous who is listening and “they” (who are generally only spoken of in their absence). As a rule, “they-ness” is easier to spot the less “they” look like the friend of Dr. Righteous.

It is easier to tell others how to act when one is standing on a pedestal or wearing some sort of ceremonial garment. Avoiding the possibility of having a conversation also helps.

Sometimes we clean up third-person ethics by removing the personal dimension. We shift from “they” to “it.” “It would be best if everyone ...” “It is obvious that ...” “It stands to reason or everyone sees the wisdom of ...” The “it” arabesque also seems to elevate the conversation to universal principles. Neat and clean, perfectly fair, just do the right thing. It only shows up in the very fine print that certain individuals are allowed to interpret which “it” is the right one.

The defensible position is the second-person perspective. You and me. We may not agree about which philosopher has the grand insights, but there is a better chance of walking out of the room in agreement than if I insist that you agree with me before you can sit down. ■

The nub:

1. Private virtues are only ethical when they make others’ lives go better.
2. Third-person scolds and ex cathedra judgments are sham ethics.
3. We can only fix it when those involved sit down and talk about it.

David W. Chambers, EdM, MBA, PhD, is professor of dental education at the University of the Pacific, Arthur A. Dugoni School of Dentistry, San Francisco, and editor of the *Journal of the American College of Dentists*.



BPA Harms Tooth Enamel in Rats, Mimics MIH

A tooth enamel abnormality in children, molar incisor hypomineralization (MIH), may result from exposure to the industrial chemical bisphenol A (BPA), authors of a new study recently concluded after finding similar damage to the dental enamel of rats that received BPA.

“Human enamel defects may be used as an early marker of exposure to BPA and similar-acting endocrine disruptors,” said Sylvie Babajko, PhD, in a news release.

BPA is an endocrine disruptor, or hormone-altering chemical, that has been linked to numerous adverse health effects in humans. It appears in many plastic and resin household products and food containers, including until recently baby bottles, sippy cups and infant formula packages.

Recent published data show that MIH affects up to 18 percent of children ages 6 to 9 years and although the cause is unclear, appears to have an environmental origin, according to the study authors.

In the first part of the study, the researchers gave rats low doses of BPA, comparable to exposure in humans. The rats received BPA from fetal life to 30 days after birth and, according to the researchers, the BPA caused enamel defects similar to MIH in humans, especially in male rats.

In the second part of the study, the investigators cultured and looked at rat ameloblast cells, which are present only during the formation of tooth enamel. In humans, amelogenesis

takes place from the third trimester of fetal development to three or four years after birth. This cell-based experiment showed that sex hormones target and influence dental epithelial cells, according to the news release.

“Our study shows, for the first time, that BPA affects dental cells, and subsequently enamel synthesis, using similar target molecules as those present in other organs,” said Babajko, who also explained that



Study Details Mouth, Heart Connection

According to research recently published online by the American Heart Association, scientists at Forsyth and Boston University have demonstrated that using an oral topical remedy to reduce inflammation associated with periodontitis also results in the prevention of vascular inflammation and can lower the risk of heart attack.

The researchers of this study demonstrated the ability of an oral treatment for gum disease to also reduce inflammation in the artery wall. The active ingredient is an inflammation-resolving molecule, known as Resolvin E1. This discovery further underscores the increasing body of evidence showcasing how problems in the mouth – and how they are treated – can have life-changing influences on other key systems in the body, in this case the heart.

“Our research is helping to underscore the very real link between oral health and heart disease,” said Hatice Hasturk, DDS, PhD, lead investigator, in a news release. “The general public understands the connection between heart health and overall wellness, and often takes appropriate steps to prevent heart disease. More education is needed to elevate oral wellness into the same category in light of proven connections to major health conditions.”

This is the first paper to show a rabbit model of accelerated heart disease, demonstrating a range of atherosclerotic plaque stages that more closely resemble those in humans without genetic modification of the animal, according to the news release.

For more information, see the study published March 19, 2015, online before print in the journal *Arteriosclerosis, Thrombosis and Vascular Biology*, 2015, 35: 1123-1133.

these molecules are receptors for sex steroid hormones involved in organ development, endocrine homeostasis and hormone-sensitive cancers. She also reported that an increase in estrogen activity had a greater effect on the tooth enamel in male rats than in female rats and said this finding suggests possible sexual differences in enamel quality.

These study results were presented in March 2015 at the Endocrine Society’s 97th annual meeting in San Diego.

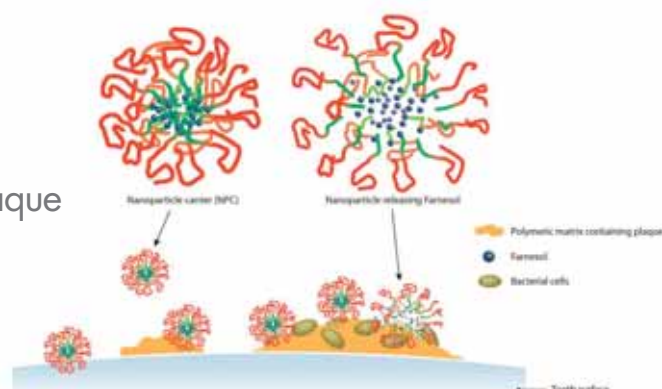
New Technique Applies Antibacterial Agent to Plaque

Therapeutic agents intended to reduce dental plaque and prevent tooth decay are often removed by saliva and the act of swallowing before they can take effect. But, according to a news release, a team of researchers has developed a way to keep the drugs from being washed away.

In a recent study, published in the journal *ACS Nano*, researchers found a new way to deliver an antibacterial agent

(farnesol) within the plaque, despite the presence of saliva.

To deliver the farnesol to the targeted sites, the team of researchers created a spherical mass of particles — constructing the outer layer out of positively charged segments of the



polymers and securing the drug with hydrophobic and pH-responsive polymers.

The positively charged outer layer of the carrier is able to stay in place at the surface of the teeth because the enamel is made up, in part, of hydroxyapatite (HA), which is negatively charged. Just as oppositely charged magnets are attracted to each other, the same is true of the nanoparticles and HA. Because teeth are coated with saliva, the researchers weren't certain the nanoparticles would adhere. But, according to the news release, not only did the particles stay in place, they were also able to bind with the polymeric matrix and stick to dental plaque.

Because the nanoparticles could bind both to saliva-coated teeth and within plaque, the researchers used them to carry the antibacterial agent to the targeted sites and found that the nanoparticles could release the drug when exposed to cavity-causing eating habits — precisely when it is most needed to quickly stop acid-producing bacteria. The researchers tested the product in rats that were infected with *Streptococcus mutans*.

"When the drug was administered without the nanoparticle carriers, there was no effect on the number of cavities and only a very small reduction in their severity. But when it was delivered by the nanoparticle carriers, both the number and severity of the cavities were reduced," said co-senior author Hyun Koo, in the news release.

For more, see the study published in *ACS Nano*, 2015, 9 (3), pp. 2390–2404.

Study: E-Cigarettes Not 'Harmless'

In a major scientific review of research on e-cigarettes, scientists at the University of California, San Francisco discovered that industry claims about the devices are unsupported by the evidence to date, including claims that e-cigarettes help smokers quit, according to a news story from the university.

In their analysis, the authors found that e-cigarette use is associated with significantly lower odds of quitting cigarettes and that while the data are still limited, e-cigarette emissions "are not merely 'harmless water vapor,' as is frequently claimed, and can be a source of indoor air pollution."

E-cigarettes deliver a nicotine-containing aerosol popularly called "vapor" to users by heating a solution commonly consisting of glycerin, nicotine and flavoring agents. E-liquids are flavored, including tobacco, menthol, coffee, candy, fruit and alcohol flavors, the authors wrote.

"E-cigarettes do not burn or smolder the way conventional cigarettes do, so they do not emit side-stream smoke; however, bystanders are exposed to aerosol exhaled by the user," according to the authors, who wrote that a previous study found low levels of formaldehyde, acetaldehyde, isoprene, acetic acid, nicotine and other toxins were measured in that aerosol. Toxins in the e-cigarette aerosol were at much lower levels compared with the conventional cigarette emissions, they noted.

The authors conclude that "evidence available at this time, although limited, points to high levels of dual use of e-cigarettes with conventional cigarettes, no proven cessation benefits and rapidly increasing youth initiation with e-cigarettes."

For more information, see the full study in the American Heart Association's journal *Circulation*, 2014; 129: 1972-1986.





Practice Support

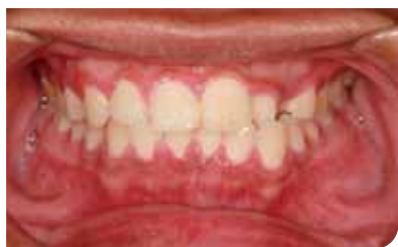Employment Practices

I've got my hands full as it is. How can I keep up on every new change in employment law?

When it comes to employment practices, there's one spot where CDA members can get assistance with every nuance of running a practice: CDA Practice Support. Download a customizable employee manual or train your staff with easy-to-use PowerPoint presentations. There are even tips on setting staff rules around piercings and tattoos. What's more, if you need personalized advice, our employment expert is just a phone call away. CDA Practice Support. It's where smart dentists get smarter.

800.232.7645 or **cda.org/practicesupport**





Graphene Oxide Effective in Killing Dental Pathogens

Dental diseases, which are caused by the overgrowth of certain bacteria in the mouth, are among the most common health problems in the world. According to a news release, scientists have recently discovered that a material called graphene oxide is effective at eliminating these bacteria, some of which have developed antibiotic resistance.

Published in the journal *ACS Applied Materials & Interfaces*, the study explains that dental caries and periodontal diseases “have a close relationship with microbes such as *Streptococcus mutans*, *Porphyromonas gingivalis* and *Fusobacterium nucleatum*.”

The authors point out that dentists often prescribe traditional antibiotics to get rid of bacteria that cause tooth decay or gum disease and that with the rise in antibiotic resistance, new approaches are needed to address these problems, which can lead to tooth loss.

Previous studies have demonstrated that graphene oxide — carbon nanosheets studded with oxygen groups — is a promising material in biomedical applications. It can inhibit the growth of some bacterial strains with minimal harm to mammalian cells.

Study Pinpoints Brain Regions Involved in Dental Pain

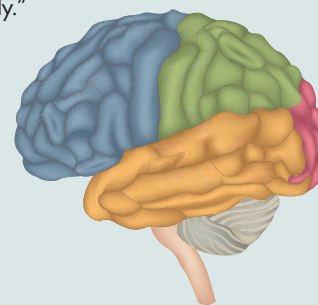
In a recent study, researchers investigated the “task-related” brain activity and functional connectivity patterns following onset of a regional anesthetic nerve block during continuous noxious dental stimulation.

For this placebo-controlled, age-matched functional magnetic resonance imaging study, 28 subjects were included (only males, mean age 27) received repetitive electric stimuli to the left mandibular canine, evoking an intensity perception of five on an 11-point numeric intensity rating scale, according to a news release.

The experiment was divided into two phases, the first consisting of 30 stimuli for a duration of five minutes followed by a submucosal injection of either the anaesthetic articaine 4% (group A) or 0.9% sodium chloride (placebo group) at the left mental foramen. The second phase consisted of electric tooth stimulation for 16 minutes, during which subjects indicated pain offset by pressing an alarm ball. In the anesthesia group, pain relief was reported 4.5 minutes after the injection whereas in the placebo group, no subject reported pain relief. Between-group analysis of phase two demonstrated “a significant activation cluster in the ipsilateral posterior insula (plns)” in the placebo group. Using the plns as a seed region, “the PPI analysis yielded a significant enhanced coupling to the midbrain (periaqueductal grey/ventral tegmental area) after analgesia onset in group A only.”

The novel paradigm applied in this study demonstrated that dental pain relief was accompanied by a significant activity reduction in the posterior insula and an enhanced connectivity to the midbrain, according to the news release.

The new data was presented March 2015 at the 93rd General Session and Exhibition of the International Association for Dental Research.



This research team wanted to see if the nanosheets would also stop the specific bacteria that cause dental diseases.

In the lab, the researchers tested the material against three different species of bacteria that are linked to tooth decay and gum disease. According to the study, transmission electron microscopy (TEM) images revealed that the cell wall and membrane of the bacteria lost their integrity and the intracellular contents

leaked out after they were treated by graphene oxide. Therefore, they conclude, graphene oxide nanosheets would be “an effective antibacterial material against dental pathogens and the potential applications in dental care and therapy are promising.”

For more information, read the study published in the journal *ACS Applied Materials & Interfaces*, 2015, 7 (9), pp. 5605–5611.

Survey: Oral Pain Specialists Treat Complex Health Issues

In a new study, authors have discovered that patients with facial pain see an average of 2.2 doctors over 17 months before visiting facial pain and oral medicine specialists. According to one author, this delay in getting treatment can allow pain to escalate from acute

to chronic and reduce the patient's quality of life dramatically.

The authors conducted a survey to better understand the work of pain specialists and to describe in detail the types of patients these specialists see in the United States. According to their survey, the authors



Xylitol in Tooth Decay Prevention Still Unproven

New research from The University of Manchester concludes that there is limited evidence to show that xylitol is effective in preventing dental cavities in children and adults, according to a news release from the university.

Xylitol is a popular sugar substitute and is already known to cause less damage to teeth than sugar. It has also been suggested that the addition of xylitol to products may help to prevent tooth decay by stopping the growth of decay-producing bacteria. However, according to new evidence published in the Cochrane Library there is little high-quality evidence that xylitol is beneficial in the fight against tooth decay.

The authors gathered together data from 10 studies that analyzed a total of 5,903 participants. In most cases, the studies used such different methods that the researchers could not combine the results to create a summary effect estimate. Based on information from 4,216 schoolchildren who took part in two Costa Rican studies, they found low-quality evidence that levels of tooth decay were 13 percent lower in those who used a fluoride toothpaste containing 10% xylitol for three years, compared to those who used a fluoride-only toothpaste. For other xylitol-containing products, such as xylitol syrup, lozenges and tablets, there was little or no evidence of any benefit.

"The evidence we identified did not allow us to make any robust conclusions about the effects of xylitol, and we were unable to prove any benefit in the natural sweetener for preventing tooth decay," said lead researcher Philip Riley, of the School of Dentistry at The University of Manchester, in the news release.

For more information, read the full review published online in the *Cochrane Database of Systematic Reviews*, 2015, issue 3, March 26, 2015.



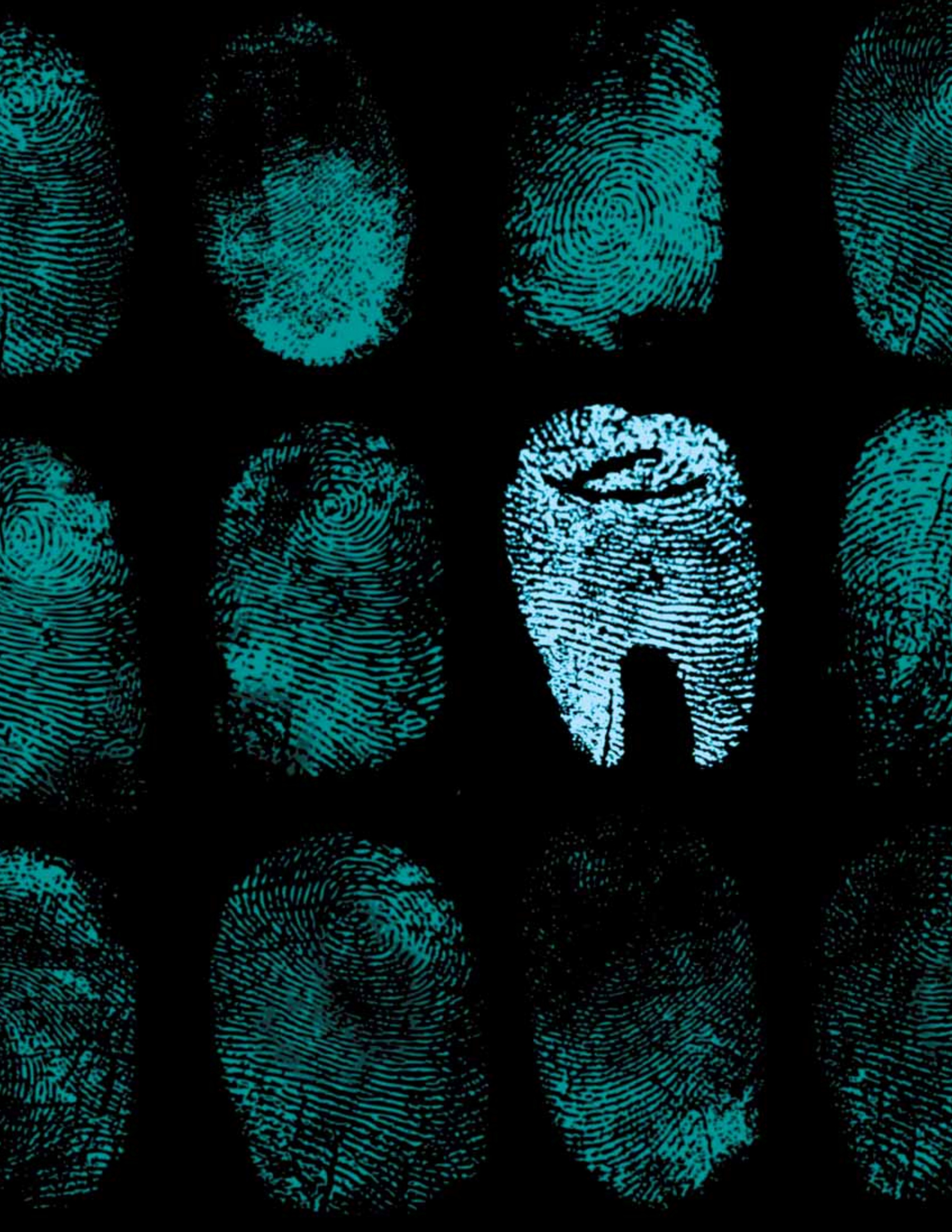found 46 percent of the specialists practiced in dental schools, 31 percent practiced in hospitals and 18 percent practiced in combined settings. Only 5 percent were in private practice.

The average age of the patients was 57 and nearly twice as many of the patients were women. The leading cause of referrals to the specialists was oral lesions, followed by orofacial pain, dry mouth, burning mouth and oral sores or ulcers, according to a news release. The tongue and gums were predominant sites for pain, but less so for teeth and lips, and about one-third of the referred patients reported pain in at least two locations.

Oral lesions and pain caused by oral lichen planus was the main reason many sought treatment, followed by problems with the salivary glands.

The pattern of patient referrals demonstrates the breadth of the interprofessional practice with ear, nose and throat surgeons, dermatologists and oncologists, general practice dentists and other health care providers, according to the news release.

For more, see the study published in the journal *Oral Surgery, Oral Medicine, Oral Pathology and Oral Radiology*, 2015; 119 (4): 408.



Forensic Odontology

Duane E. Spencer, DDS

GUEST EDITOR

Duane E. Spencer, DDS, practices pediatric dentistry in Walnut Creek, Calif. He is a forensic dental consultant to Alameda, Contra Costa, San Mateo and Solano counties and the California Department of Justice.
Conflict of Interest
Disclosure: None reported.

"They're dentistry's detectives, a small group of professionals who lend their skills and training to the often grisly business of helping identify crash victims, solve rapes and catch killers. Their names and faces may appear in the news, but there's little glamour in the job. It's mainly hard work, dedication and attention to detail."

This caption was on the cover of the September 1989 issue of the *Journal of the American Dental Association*, titled "Forensic Dentistry."

It is seldom that a dental journal is dedicated entirely to the field of forensic odontology. Although an occasional article on the subject may appear, the last issue of the *Journal of the California Dental Association* devoted to forensics was August 2004. That award-winning issue, with articles submitted in 2003, was largely related to the terrorist tragedies of Sept. 11, 2001. Three authors from that issue, Anthony "Rick" Cardoza, DDS; Gregory S. Golden, DDS; and James D. Wood, DDS, have contributed to this issue.

Forensic odontology continues to be a relatively small field of dentistry. Most dentists give the subject little thought, unless they receive a call from their local county coroner/medical examiner requesting a patient's dental records or perhaps contemplate obtaining continuing education hours at a forensic dental presentation. There are currently only a few dozen dentists in California who have experience in the field and only 14 who are American Board of Forensic Odontology (ABFO) certified. There are about 100 ABFO-certified odontologists in North America. Although the numbers are small, most jurisdictions have access to qualified forensic dental consultation. Many odontologists continue working in the field after they retire from their private dental practices.

It is the goal of this issue to not only offer the reader articles on the mainstay of odontology and dental identification, but to cover subjects that might be new and of interest. Five articles comprise this issue, each submitted by very experienced authors in the field. All dental authors are diplomates of the ABFO and are active in the organization.

Roger D. Metcalf, DDS, JD, and Janice Klim-Lemann, DDS, authored “Overview of Forensic Odontology,” which is an introduction, as well an excellent overview, of odontology. Dr. Metcalf is the director of the human identification lab and chief forensic odontologist for the Tarrant County Medical Examiner in Fort Worth, Texas. He is the recent chair of the ABFO certification and examination committee and president of the American Society of Forensic Odontology. Dr. Klim-Lemann practices general dentistry in Redlands, Calif. She participated in the identification efforts after 9/11 and is a consultant with the California Department of Justice.

Drs. Cardoza and Wood combined their experiences in “Atypical Forensic Dental Identifications.” As the title implies, actual interesting identification cases are presented with photographs. Dr. Cardoza has a general dental practice in El Cajon, Calif., and is a forensic consultant for Imperial and San Diego counties and the California Department of Justice. He is a frequent presenter in the field of forensics to local, state and national dental societies/associations. California State Assemblyman (District 2) Dr. Wood is the forensic dental consultant to five North Bay California counties. As the founding director of the California Dental Identification Team (CalDIT), he also participated in the Disaster Mortuary Operational Response Team (DMORT) identification efforts in 9/11 and post-Hurricane Katrina.

Dr. Golden authored “Bite-Mark and Pattern Analysis.” He practices general dentistry in Rancho Cucamonga, Calif, and is an ABFO past-president and a past chair of the ABFO certification/examination committee. He is the chief forensic odontologist for San Bernardino County as well as consultant

to other Southern California counties. Dr. Golden is a co-author of the bite marks chapter in the fifth edition of the *Manual of Forensic Odontology*. He has also taught the bite mark component and advanced photography seminar at the Symposium of Forensic Dentistry at the University of Texas, San Antonio. Due to a recent number of exonerations of people convicted of crimes where bite-mark evidence was involved, there is, rightfully, attention focused by many on the status and future of bite-mark analysis. Dr. Golden contributes an up-to-date overview of bite-mark analysis and discusses the current recommendations, concerns and opinions on this important issue.

Forensic dental age estimation is a subject that is probably new to most readers. Dental age estimation is important not only in identification efforts but also in estimating the age of an individual who may enter the criminal justice system without papers. Is he/she a juvenile or an adult? James Lewis, DMD, and David Senn, DDS, co-authored “Forensic Dental Age Estimation: An Overview.” Dr. Lewis practices general dentistry in Madison, Ala. He is the forensic dental consultant to the Alabama Department of Forensic Sciences in Huntsville. He also directs the dental age estimation workshop for the ABFO. Dr. Senn is a past ABFO president. He is a clinical assistant professor at the University of Texas Health Science Center at San Antonio and is the director of the Center for Education and Research in Forensics (CERF). Drs. Lewis and Senn also co-authored the chapter on dental age estimation in the current edition of the *Manual of Forensic Odontology*.

Kenneth Cohn, DDS, and Ron Berman, BA, CFE, wrote “The Forensic Dentist: A Basic Overview

of Expert Roles in Animal Bite-Mark Investigation.” Having worked on numerous fatal animal attack cases in California over the years, it seemed readers might be interested in an article on animal bite marks. Dr. Cohn has a general dental practice in The Villages, Fla. He is a consultant to multiple medical examiner districts in Florida and is a past president of the International Veterinary Forensic Science Association. Dr. Cohn authored the chapter “Animal Bitemarks” in the fifth edition of the *Manual of Forensic Odontology*. Mr. Berman is a canine behavioral consultant and trainer providing expert witness services for forensic investigations and litigations of dog bites and pet-related injuries, specializing in Rottweilers and pit bulls. He has participated in more than 700 cases.

It is the hope of this guest editor that readers will gain further information concerning forensic odontology. This issue can also serve as a reference for those in forensic fields outside of dentistry such as law enforcement and pathology. ■



Overview of Forensic Odontology

Roger D. Metcalf, DDS, JD, and Janice Klim-Lemann, DDS

AUTHORS

Roger D. Metcalf, DDS, JD, is a forensic dentist practicing in Fort Worth, Texas. He is the full-time forensic odontologist and director of the human identification laboratory for the Tarrant County medical examiner's district. He is board certified by the American Board of Forensic Odontology (ABFO) and is the immediate past-chair of the ABFO Certification and Examination Committee. He is currently the president-elect of the American Society of Forensic Odontology.

Conflict of Interest

Disclosure: None reported.

Janice Klim-Lemann, DDS, is a general dentist in Fontana, Calif. She has been a forensic dentist for 10 years and assisted at the World Trade Center after 9/11, helping to identify victims. She is a diplomate of the American Board of Forensic Odontology (ABFO), a fellow of the American Academy of Forensic Sciences (AAFS), a member of the American Society of Forensic Odontology (ASFO), the California Dental Identification Team (CalDIT) and the California Society of Forensic Dentistry (CSFD).

Conflict of Interest

Disclosure: None reported.

It's 8 a.m. on Monday, and you're all ready to start on a 10-unit crown and bridge case. But suddenly your office manager appears at the operatory door and wants to speak with you now. Out in the hallway she tells you that there's a deputy from the sheriff's office waiting in the reception area. He's presented a subpoena and would like to have Mrs. Jones' dental records. Your mind races ... you begin to think: "Why does he want her records? Did I do something wrong? Do I need to call my attorney? Maybe my malpractice insurance carrier? Do I have to give him the records? Let me think ... what treatment did I do for Mrs. Jones?"

Those were exactly the types of questions running through our minds the first time dental records for one of our patients were requested by a medical examiner's (ME) office for identification purposes.¹ If and when this ever happens, once your initial angst subsides, you will find that the field of forensic dentistry is very fascinating — not as it is portrayed on television shows — but fascinating nonetheless.

As our dental schools' curricula are now packed with courses emphasizing

required basic science information and critical clinical skills, the amount of time available for introduction to niche areas such as forensic dentistry has become very limited. Many practitioners may not be completely aware of the full spectrum of practice encompassed by modern forensic dentistry, also known as forensic odontology. Most dentists probably know that unidentified human remains can be identified via dental records in some way. And, some are also likely aware that occasionally when a defendant was convicted of some heinous crime, part of the evidence presented at trial by the prosecution was a bite-mark analysis. To be sure, the majority of cases that forensic dentists are involved with center on either the identification of human remains or a bite-mark analysis, but the broad field of forensic odontology encompasses far more than just those two areas.

So, how much more? And exactly what does it cover? Who are these "forensic odontologists"? Where can one learn more about this interesting field? How can one become more involved as one of these dentists-turned-detectives?

We're glad you asked.

Identification of Human Remains via Dental Records

A serial killer has been on the loose, and the police have tracked him down and surrounded him in a cabin in the mountains. A fire accidentally breaks out at the scene and completely burns the cabin to the ground. Human remains are recovered, but are not visually identifiable due to thermal damage. In addition, the decedent's fingers have been burned so badly a fingerprint comparison for identification is simply not possible. Law enforcement and the public are anxious to know if the deceased person is indeed the wanted serial killer — and they want to know now. The media quickly reports the decedent has been positively identified as the wanted suspect, and the identification was made by a forensic odontologist using dental records.

While this is the sort of scenario that is probably the best known to the public, it is just one part of the forensic odontology discipline. Forensic odontology is one of the five methods generally accepted for forensic identification of unidentified remains in most U.S. jurisdictions. In addition to identification via dental records, the other four methods are:

- Visual ID either by a relative or by use of some acceptable photo document.
- Identification by fingerprint comparison.
- Identification by anthropological means (typically comparison of ante- and postmortem medical radiographs).
- Identification by analysis and comparison of DNA samples.

There may be other methods that are acceptable in some limited circumstances, such as identification by distinctive marks or tattoos on the decedent's body, or identification by comparison of serial numbers on implanted surgical hardware or cardiac pacemakers. It should be noted that once the odontologist

has given his or her opinion and made a recommendation, the actual certification of a decedent's identity falls to either the coroner/ME or a judge.

It has been said that teeth are the part of a human body most susceptible to disease during a person's life, yet are the most durable part after a person's death. This characteristic makes the dentition extremely useful for identification purposes. Severely decomposed or burned individuals are commonplace in most morgues. It is with these types of cases that the forensic odontologist can be

Forensic odontologists can easily distinguish between siblings and even between identical twins.

most helpful in establishing identity, as visual identification is usually not possible, or the decedent's fingers may be too damaged to obtain satisfactory postmortem fingerprints. Complicating the situation further, even if suitable postmortem samples can be obtained, known antemortem fingerprints for comparison simply may not be available. Nuclear DNA may be too degraded to develop a satisfactory postmortem DNA profile of the deceased or an antemortem DNA profile of the decedent or the decedent's family members may not be available for comparison. Additionally, even if the decedent's nuclear DNA profile can be developed and compared to a family reference sample, the typical parentage-type nuclear DNA analysis cannot distinguish a particular

individual from his or her siblings (unless, rarely, a known antemortem sample of the decedent's own DNA is available for a direct comparison) and cannot distinguish between identical twins. Analysis and comparison of mitochondrial DNA profiles is less powerful statistically than comparison of nuclear profiles. Another limitation is the relatives being compared using mitochondrial DNA must also be maternally related to the decedent. Both mitochondrial and nuclear DNA analyses are relatively expensive to perform and, due to backlogs in many government labs, it may take an inordinate amount of time to get the results. Forensic dentists can render very valuable assistance in these situations.

Forensic odontologists can easily distinguish between siblings and even between identical twins. If suitable antemortem records can be located, identification of remains using dental records may be possible and can be performed quickly, reliably and on a cost-effective basis. However, the downside is that some information must be known about the tentative identification of the decedent in order to interview family or friends to learn the identity of the treating dentist. Sometimes that information is readily available and sometimes it is not. Sometimes the treating dentist can easily be located, sometimes not.

The forensic odontologist called to the morgue will perform many dental examination procedures, such as charting existing restorations, missing teeth and taking radiographs and photographs, just as if the decedent were a living patient in the office. However, unlike with a living patient, certain conditions, such as rigor mortis or advanced decomposition, can make the postmortem examination rather challenging.

If the putative decedent's treating dentist can be located, and if appropriate records are obtainable, the odontologist will compare the ante- and postmortem records. Depending on convention in a particular jurisdiction, the odontologist may take the lead in locating and obtaining antemortem records or the ME/coroner investigators may be responsible for obtaining these records.

The three things an odontologist will look for when comparing these written and radiographic records are consistencies, explainable inconsistencies and unexplainable inconsistencies.

Consistencies are, of course, conditions that are the same between the ante- and postmortem records. Inconsistencies are conditions that are not the same between the antemortem and postmortem records — for example, tooth No. 3 may have an O amalgam noted in the antemortem chart, but is found to have an MO composite upon postmortem exam. This is an inconsistency, but it is explainable by the normal course of dental treatment and does not rule out a positive ID. However, if tooth No. 14 has had a full crown placed antemortem, but is a virgin tooth on postmortem examination, then this would be an unexplainable inconsistency that would preclude a positive ID, assuming the ante- and postmortem records are accurate and correct. The trained forensic odontologist will compare the antemortem and postmortem records tooth by tooth and develop an opinion as to whether or not the comparison results in a positive ID.

One of the most well-known early cases of dental identification of unidentified remains, and probably the first in North America, is that of Gen. Joseph Warren of Massachusetts. Gen. Warren was a patriot, physician and distinguished military leader during the Revolutionary War, and was the colonial leader who sent Paul Revere on

the celebrated "Midnight Ride." Gen. Warren was later killed in the legendary Battle of Bunker Hill (which actually took place mostly at Breed's Hill). His body was mutilated and roughly buried by the British in a mass grave. His family later wanted to exhume his body so he could be reburied properly with appropriate recognition. His remains were eventually recovered by his brothers and identified as Dr. Warren by Paul Revere, who was a dentist as well as silversmith. Revere reportedly had made a dental prosthesis from a walrus tusk for Warren.

The trained forensic odontologist will compare the antemortem and postmortem records tooth by tooth.

In today's world, the final forensic dental opinion usually relies on the comparison of postmortem records to antemortem records. Thus, it is extremely disheartening for the ME/coroner investigator or the forensic odontologist to obtain information from the putative decedent's family about the decedent's dentist, only to locate and call that dental office and be told "Oh, I'm so sorry, we saw that patient for several years, but his films and records were shredded a couple of years ago." Please archive and don't destroy your patients' old records. While we understand that traditionally archiving hard copies of charts and films can be a bit cumbersome, in today's computerized world, long-term storage of digital files and images essentially requires only some space on

a computer's hard drive. In California, dentists are not required by statute to archive records, but the American Society of Forensic Odontology (ASFO) has issued a position paper on records retention that encourages dentists to maintain and archive all dental records, particularly radiographs, indefinitely.

One of the seminal, defining moments in the development of organized forensic dentistry in the U.S. was the Big Thompson Canyon flood that occurred on July 31, 1976, in Colorado. It has been described as one of the worst flash floods in U.S. history. One hundred and forty-four victims lost their lives and five people were never found. Forensic dentists participated in identifying the deceased, and this was reportedly the first occasion a computer program was used to assist in comparing ante- and postmortem dental records. In addition to natural disasters such as floods, forensic dentists will also be mobilized to assist with identification of victims in a number of other large-scale incidents — including natural events such as a tsunami or earthquake or man-made disasters such as the intentional and criminal destruction of a populated skyscraper or airliner. In these cases, the dentally related disaster victim identification (DVI) procedures employed are still the same dental identification procedures used when identifying a single individual at the morgue, but with the organization and logistics on a larger scale. Duties may be shared and delegated among many dentists with a formal organization hierarchy implemented. The dentists may be deployed to a distant, remote site where the infrastructure of basic utilities has been destroyed or is literally nonexistent, rather than reporting to a morgue near home. Several government agencies with overlapping jurisdictions may be involved in a large incident,

perhaps local, state and federal, and the incident might be treated as a criminal investigation. If the incident is very large scale and involves international victims, agencies of other countries may expect to be involved in the investigation, as well. The time frame for resolution of the incident may be on the order of weeks to months instead of a few hours or days. Media scrutiny may be intense.

Dentists also may be asked by investigators or family members to assist with a missing person or unidentified person case by releasing a patient's records to the appropriate authority, such as a police department or coroner's office. Information about a missing person, including a dental profile, may be entered in various databases by law enforcement or another appropriate agency. Coroner and ME offices may upload information about unidentified human remains. The entries from both the missing and the unidentified persons' databases can be compared periodically to determine by various criteria if there are potential matches between them. One such federal database is the National Crime Information Center (NCIC) operated under the Criminal Justice Information Services Division (CJIS) of the FBI. Access to NCIC is open only to approved law enforcement agencies, and the information contained is not available to the public. California's state database is administered in Sacramento by the Missing and Unidentified Persons (MUPS) division at the California Department of Justice (DOJ). Another useful database is the National Missing and Unidentified Persons System (NamUS) administered by the University of North Texas Health Science Center in Fort Worth for the National Institute of Justice (NIJ). Entry of information into NamUS is voluntary for law enforcement agencies and

coroner/ME offices, whereas participation with NCIC may be mandatory for the agencies by statute. The advantages of NamUS versus NCIC are that NamUS is more "user friendly," and the missing persons' component of NamUS is accessible to the public for data entry and perusal. Dentists may be requested to provide a patient's records to an agency so the information can be uploaded, or may even be asked to prepare the NCIC or NamUS entry for the agency. The Health Insurance Portability and Accountability Act of 1996 (HIPAA)

Bite-mark analyses are extremely useful and powerful in excluding certain suspects.

has a specific exclusion (CFR 45 §164.512 (g)(1)) that allows a "covered entity" to release information about one of its patients to a coroner/ME office for ID purposes without any consent required (note that while the dental records do belong to the dentist, it is a well-established law that such records must be released to the coroner/ME upon a properly presented request). For these database comparisons to work properly, it is imperative that the dental information be entered correctly. Training in NCIC and NamUS dental coding is available from the respective agencies as the proper coding of antemortem versus postmortem dental records is not always intuitive or straightforward. A local diplomate of the ABFO will be glad to assist with this coding, as well.

Bite Marks

A baby is brought to the hospital having suffered several serious injuries including broken ribs and broken limbs. The emergency department physicians and nurses are immediately suspicious about the mother's explanation of the wounds — she says the baby fell off of a couch onto a carpeted floor. The police detectives consider her boyfriend a "person of interest." Unfortunately, the baby dies. The coroner is duly notified and takes jurisdiction of the decedent. At autopsy, the forensic pathologist notices injuries consistent with a sexual assault. Additionally, there are several injuries that resemble human bites. The coroner calls in a forensic odontologist. The forensic odontologist examines the baby and takes photos of these patterned injuries. Later, the photos are compared to dental models from the boyfriend. The odontologist unequivocally excludes the boyfriend. Other suspects must now be considered. DNA profiles developed from swabs of the bite-mark injuries and from the sexual assault examination taken at autopsy are later found to be consistent with the profile of the baby's biological uncle. He is arrested and charged with sexual assault and murder.

This scenario depicts one of the very important, and very often overlooked, functions that a competent forensic odontologist can serve in the criminal justice system — protecting the innocent. Bite-mark analyses are extremely useful and powerful in excluding certain suspects. While exclusion of a suspect may not initially seem important in the overall scheme of things, it is profoundly important to the accused individual who is excluded, and is just as important to investigators seeking to apprehend the proper suspect. Further, a district attorney's first job is to ensure that justice is done. No prosecutor has an interest in pursuing an investigation against and prosecuting an innocent person.

Not every suspicious injury examined will turn out to be a bite mark and not every actual human bite mark will be suitable for analysis and comparison. Before embarking on a bite-mark analysis or comparison, the analyst should be well trained and well prepared. Bite-mark cases are commonly involved with heinous crimes, such as the death of a child or a brutal sexual assault, and the stakes in these cases are often high, literally, life-or-death consequences in states that have the death penalty. The bite-mark analyst will most likely be called to testify if the case goes to trial. It is not hyperbole to say these cases can be extremely stressful for all involved.

In some bite-mark cases, the odontologist may be able to opine to some particular degree of belief that a certain suspect may have made the bite mark on a victim (note that occasionally the roles may be reversed and the crime victim may have bitten the suspect). Such linkage can be very important in an investigation, as this could indicate in some instances the suspect was with the victim perimortem (i.e., around the time of death), a temporal finding DNA cannot show. Additionally, a bite mark could show the suspect used a great deal of force to inflict an injury that caused the victim pain and suffering. Further, finding a suspect's DNA on a victim may not be probative in a family/friend situation (it might not be unusual to find the suspect's DNA on the victim in these situations and vice versa), but presence of a bite mark is not so easily explained.

There have been some high-profile bite-mark-cases-gone-bad that were publicized recently, which have made some critics opine it is time for this discipline to be discarded. Most of these cases seem to be when the forensic odontologist involved testified that the suspect made a bite mark on the victim, the suspect was then convicted of a heinous crime,

and years later DNA analysis showed the convicted defendant could not have been the actual perpetrator. Some of those cases are indeed inexcusable. However, note that many of these cases were tried before today's modern techniques and standard operating procedures were in place. Some of the early analysts essentially worked in a vacuum, with little formal training and very little organizational support. Over the years, professional odontology groups have recognized and learned from mistakes made in the early days. They have taken and are taking corrective and preventive

Consultation and collaboration with competent peers when one is analyzing a bite-mark case are strongly encouraged.

actions. In fact, it has been members of the ABFO who have provided requested expert assistance to the wrongly convicted defendant in many of these cases. The challenges have been noted, taken to heart and the pertinent issues are being addressed. Standardized written guidelines, recommended methods and procedures, vetted standards and best practices have been adopted and promulgated by the ABFO, the leading forensic odontology certification organization. Consultation and collaboration with competent peers when one is analyzing a bite-mark case are strongly encouraged. Appropriate fundamental research in the subject is being proposed and performed. Very stringent requirements must be met in order to challenge the ABFO certification examination. The discipline has evolved

and practitioners have improved over the years, and the current critical examination of this area of practice can only result in continued improvements. We believe an exciting new era in this forensic science area is about to begin with the recent appointment of the Odontology Subcommittee of the National Institutes of Standards and Technology (NIST) Organization of Scientific Area Committees (OSAC). We are confident the field of bite-mark analysis will survive the critical examination it is currently undergoing because, even as detractors agree, it offers a powerful method to exclude the innocent in many cases. Even if for no other reason than just that one alone, the field should not be abandoned. The modern discipline of bite-mark analysis and comparison is simply not practiced the same way it once was, and we believe frank and careful evaluation of this forensic specialty will ultimately result in many more desirable improvements.

In consideration of the foregoing, it is our suggestion that one should not take a bite-mark case lightly or without carefully considering the potential ramifications. The consequences of a bite-mark analysis gone wrong could be disastrous for all parties involved — including professional sanctions and even steep monetary penalties, as there should be, for an incompetent odontologist found to be liable for performing a faulty bite-mark analysis.

Age Estimation

A house fire has claimed the lives of a mother and her three sons. All four victims are very badly burned. The mother has had dental treatment in the past and her dental records are available. Because she is the only known female adult in this incident, her remains are quickly identified by the odontologist. However, after the mother and father divorced several years ago, she had not taken the boys, ages 6, 10 and 14, to the dentist and no dental records exist for the children. DNA reference

profiles are obtained from the father and from the mother's remains. Analysis shows the DNA profile of each child is consistent with being a biological child of the father and the deceased mother; this routine DNA analysis, however, cannot specifically individualize the remains. The best this analysis can tell us is that the child is a child of the parents, but not which child he is. In addition, because the remains are so badly burned, size of the remains is not a reliable indicator of which child is which. The forensic odontologist is able, though, to provide a straightforward prediction of which child is which based on dental age estimation procedures.

The two primary areas of forensic odontology practice traditionally have been identification of human remains and bite-mark analysis and comparison. Age estimation also has been performed by forensic dentists for many years, but has recently become an increasingly important area of odontology. For example, estimation of the age of human remains can assist in determining the identity of an unidentified decedent. There have been many methods developed for predicting the age of an individual based on his or her dentition. Some of the characteristics evaluated involve measurements such as root transparency, which requires the sectioning of a tooth, or measuring and counting certain internal anatomical landmarks within a tooth. These destructive methods are appropriate only for deceased subjects. However, the recent area of interest has been estimating the age of living subjects. Pedodontists and orthodontists have an armamentarium of various methods to use for estimating the dental age of patients, and some of these have been adapted for forensic use. For odontologists, the request for an age assessment can arise in cases such as refugee children who do not know their own true age, in cases of illegal immigrants who do not tell the

truth about their age, or with youthful-appearing criminal offenders who lie about their age because juveniles are treated separately and more leniently in the legal system than adults. There are various dental development charts and software programs available for the odontologist to use for estimating the age of a living subject. However, these methods all typically involve analysis of radiographs of the subject's teeth. Obtaining dental radiographs that are not for a true diagnostic or therapeutic purpose, but that are strictly for an administrative

Remember, forensic odontology in the real world is not as it is portrayed on television. It is not easy and sanitary.

proceeding such as estimating the age of a person for an immigration investigation, is considered by many to be unethical for the practitioner, and is actually illegal in some jurisdictions, as well (see Texas Administrative Code §289.227(c)(2); consider whether or not the subject is actually a patient of the odontologist). The estimate provided by many of these methods may be given as either a point estimate with standard error, such as "10 years \pm three years," or might be a point estimate with a probability, such as "there is a 65 percent probability this person is 16 years old." This type of estimation range may be acceptable in civil legal cases, but may not be accurate enough for use in criminal cases. Age estimation is currently a fairly active area of odontology research.

Organized Forensic Odontology

If after reading this introduction you've decided to explore the field of forensic dentistry a bit more, we certainly encourage you to do so. Please read the other articles written by well-regarded practitioners in this issue. Check out organizations such as the American Society of Forensic Odontology at asfo.org or a certification organization for forensic odontologists such as the ABFO at abfo.org. California has the most board-certified odontologists of all 50 states; locating a nearby odontologist to answer your questions should be fairly straightforward (check the ABFO website for members and their locations). California has a rich heritage in forensic odontology beginning with true giants in the field such as the late Reidar Sognnanes, DDS, MS, PhD, and Gerald Vale, DDS. Norman "Skip" Sperber, DDS, is one of the founders of the ASFO and an early diplomate of the ABFO. He was a first co-editor of the *ASFO Forensic Odontology Workbook*, the book destined to evolve into the highly regarded *ASFO Manual of Forensic Odontology* (to order a copy of the current edition go to the ASFO website). Join the ASFO and the American Academy of Forensic Sciences (AAFS, aafs.org). If you are really serious about pursuing forensic odontology, fulfill the qualifications and take the examination to become board certified by the ABFO. It is by no means an easy or quick process, but is very gratifying. In the future it is possible board certification may be required in order to practice in the discipline. You might look at applying for membership with a DMORT team — the federal Disaster Mortuary Operational Response Teams. These regional teams are deployed in the event of large-scale disasters such as hurricanes, tornados or floods. There are also state ID teams such as the California Dental Identification Team (CalDIT) and the California Society of Forensic

Dentistry (CSFD) you might explore. One way to get a good introduction to this discipline is to attend a training course such as the biennial Southwest Symposium on Forensic Dentistry, held in even-numbered years at the University of Texas Health Science Center at San Antonio Dental School (utforensic.org).

Remember, forensic odontology in the real world is not as it is portrayed on television. It is not easy and sanitary. Sometimes it is physically demanding work under the most challenging conditions. Sometimes we are deployed to remote locations with no basic amenities. The condition of the remains is often very unpleasant. Dealing with so many

deceased victims, especially children, is overwhelming for some. The mental stresses are great. The crimes we are witness to are often horrific. Frankly, no one is likely to become rich from practicing forensic odontology. In fact, a very significant investment of time and money for training may be required in order to get started in the field, and one might spend a lot of time as an unpaid "volunteer."

To be blunt, it is not easy to establish oneself and practice in the field of forensic odontology, and there are only a handful of full-time positions available in the U.S.

You might be wondering, "Why do you do it?" Because, for those of us who choose to practice forensic odontology, there is no

better feeling than being able to help in some way, be it with law enforcement or by assisting a family in getting closure to some very awful, tragic event in their lives and helping them begin the healing process. ■

REFERENCE

1. The local medico-legal authority may vary from jurisdiction to jurisdiction. In some states the Medical Examiner is the investigating authority, while in others the Coroner is the official designated to investigate sudden, violent, or otherwise unexpected deaths. In California, for example, the Coroner's Office is administratively a part of the Sheriff's Office in many counties. See California Government Code §27490-27512.

THE CORRESPONDING AUTHOR, Roger D. Metcalf, DDS, JD, can be reached at rmcmetcalf@tarrantcounty.com.

DentalPost

Visit www.DentalPost.net to learn more

Connect with us!



Find Your Next Employee With DentalPost!

THE PREMIER
MOBILE & ONLINE DENTAL EMPLOYMENT RESOURCE

Look what we have to help you!

Post

- Post your available jobs
- Postings syndicated to multiple networks
- 30 day job posting start at \$79!

Search

- Search resumes online and on your mobile device
- **View candidates' photo, personality test, culture, values, skills, and more!**
- Search by position, zone, education, and more

Hire

- Hire right from our site
- View applications anywhere, anytime
- Use our metrics to ensure a better fit!

2015

MASTER ESTHETIC DENTISTRY CONTINUUM

September 13, 2015 - June 6, 2016



Loma Linda University Division of Continuing Dental Education is proudly presenting the Master Esthetic Dentistry Continuum (MEDC). The 2015 MEDC offers 250 hours of lectures, hands-on workshops, online sessions, case presentations, and literature reviews.

The 10-month program (1.5 on-site days per month) provides the participants with the most up-to-date information, techniques, experience and knowledge from some of the most sought after experts in the field of esthetic dentistry. The curriculum is designed to prepare the participants to take the International Academy for Dental Facial Esthetics/International Academy of Cosmetic and Esthetic Dentistry Fellow Membership Examination.

The program is unique in that it takes a systematic and interactive approach to esthetic and cosmetic dentistry, through evidence-based case presentations.

This comprehensive Continuum covers contemporary esthetic and restorative dentistry, from a view of the latest materials to photographic skills and digital patient presentations, and will provide an in-depth review of esthetic therapies and treatments that can be immediately incorporated into the dental practice. It will expose participants to the latest equipment, materials and techniques, and provide in-depth hands-on experience and training in the latest treatment options and modalities. Each attendee will participate in case presentations on June 6, 2016

The fundamental objective is to have each participant leave the Continuum with the ability to immediately use the esthetic, restorative, and operative skills acquired through lectures and workshops. Participants will have the opportunity to build their confidence and knowledge in esthetic dentistry that they can incorporate into their dental practice, and provide their patients with comprehensive esthetic dentistry options.

COURSE DIRECTORS

SPEAKERS AND TOPICS



**Viviane S. Haber, DDS
FACD, FIADFE, FPFA**

Assistant Professor
Restorative Dentistry

Loma Linda University
School of Dentistry



**Peter S. Young, DDS
FAGD, FIADFE**

Assistant Professor
Restorative Dentistry

Loma Linda University
School of Dentistry

Credit: 250 hours of CDE credit
Tuition: \$13,950 per person
Deposit of \$7,000 required to confirm registration; remaining amount due by **September 1, 2015.**

For more information call the
Office of Continuing Dental
Education at **909-558-4685**

ON-SITE

(ALL DAY SUNDAY AND HALF DAY MONDAY)

**Nicholas C. Davis, DDS,
MAGD, FAACD, FIADFE**
September 13 and 14, 2015
Smile Design, Indirect Restorations

Stephen R. Snow, DDS, FAAED
October 4 and 5, 2015
*Mastering Digital Dental Photography:
Cameras, Computers, and Consultations*

**George Freedman, DDS,
FAACD, FACD, FIADFE**
November 1 and 2, 2015
*Dental Materials and Techniques:
New and Improved*

Fay Goldstep, DMD, FACD, FIADFE
November 1 and 2, 2015
*Diagnostics, Bioactive Materials and
Remineralization*

**Joyce L. Bassett, DDS, FAGD,
FAACD, FICDE**
December 13 and 14, 2015
*Aesthetics Built to Last: The Synergy
of Esthetics and Function in All
Ceramic and Composite Applications*

**Ziv Simon, DMD,
MSc, Dip.ABP**
January 24 and 25, 2016
*Soft Tissue Esthetics and Essential
Periodontal Procedures*

**David Hornbrook, DDS, FAACD,
FACE**
February 21 and 22, 2016
*Porcelain Veneers: Plan, Prep and
Provisional*

March 13 and 14, 2016
*Porcelain Veneers: Lab
Communication and Cementation*

Joseph Kan, DDS, MS
April 10 and 11, 2016
*Decoding Anterior Implant Esthetics:
the Ortho-Perio-Restorative
connection*

**Corky Willhite, DDS,
FAGD, FACD, FAACD**
May 15 and 16, 2016
*Anterior Composites and Transitional
Bonding: Non-traditional Composite
Restorations for Major Occlusal and
Esthetic Changes*

Steve J. Anderson
June 5, 2016
*The Art and Science for Case
Presentation*

**Peter S. Young, DDS
FAGD, FIADFE**
June 5, 2016
Being a Dental Leader

ONLINE

(90 MINUTE EVENING SESSIONS)

Steve J. Anderson
*The Art and Science for Case
Presentation*

Mark Estey, DDS
*Removable Partial Dentures and
Esthetics*

**Viviane S. Haber, DDS, FACD,
FIADFE, FPFA**
Color Character

Jim McGuire, CDT
Shade Selection

Steven R. Snow, DDS, FAAED
Simulation as a Diagnostic Tool

Marilyn Ward, DDS, FAGD
Teeth Whitening

Gerald Denehy, DDS, MS
*Direct Realignment - A Conservative
Alternative to Orthodontics*

Dan E. Fischer, DDS
Adhesive Dentistry

John Kois, DMD, MSD
The Kois Dentofacial Analyzer

Nelson A. Rego, CDT
Which Ceramic When

**Richard Trushkowsky, DDS, FAGD,
FICD, FACD, FADM, FPFA**
*Pathways for Restorative Success
- Class II Composite Resins and
Cements*



LOMA LINDA UNIVERSITY
School of Dentistry



Atypical Forensic Dental Identifications

Anthony R. Cardoza, DDS, and James D. Wood, DDS

ABSTRACT Forensic dental identification specialists are typically the last conventional option for postmortem identification. Forensic dental identification is most often accomplished by comparing radiographs of the decedent's teeth with the dental radiographs obtained from the dentist of the suspected victim. Unfortunately, antemortem dental radiographs are not always available. When presented with this challenge, the authors of this article have been successful in completing identifications using means other than dental radiographic comparison.

AUTHORS

Anthony "Rick" Cardoza, DDS, is a forensic dental consultant for the County of San Diego Medical Examiner, Imperial County Coroner, California Department of Justice and director of the California Dental Identification Team.
Conflict of Interest
Disclosure: None reported.

James D. Wood, DDS, is a forensic dental consultant for five Northern California counties and the California Department of Justice, Missing/Unidentified Persons Unit. He is a member of Disaster Mortuary Operational Response Teams, DMORT. Dr. Wood is also a member of the California Assembly, representing the second district.
Conflict of Interest
Disclosure: None reported.

Forensic dental identification specialists are typically the last conventional option for postmortem identification.

DNA is also utilized, but due to the high cost and the extensive time required for analysis, it is used sparingly or when absolutely no other option exists. Other forms of postmortem identification include visual, personal effects, fingerprints, scars, marks, tattoos, medical radiographs and, of course, dental.

Forensic dental identification has been successful because of the nature of the human dentition. Enamel is the hardest substance in the body and the only exposed portion of the skeletal system (**FIGURES 1** and **2**). Teeth are very resistant to thermal damage and blunt force trauma, and the dentition remains stable during tissue decomposition. The dentition is unique to a specific individual. This includes not only the morphology of the coronal portion

of the tooth but also the morphology of the roots, pulpal chamber and their relationship to their surrounding structures (i.e., sinus proximity, mandibular canal proximity, interproximal bony trabecular patterns, etc.). Following the natural dentition, if you add man-made dental restorations, the unique combination for any given individual is greatly magnified.

There are numerous reasons for identifying the deceased. A legal certification of death is necessary to consummate legal matters such as life insurance, business transitions, wills, etc. There are family and personal reasons as well. In criminal investigations, it is important to establish the identity of the victim in order to proceed with the criminal investigation and to identify the suspect. In a fire, bodies are often burned beyond visual recognition (**FIGURE 3**). Personal effects are also destroyed or lost in a fire. Even if the personal effects are recovered, they may not be considered reliable due to the typical calamity that

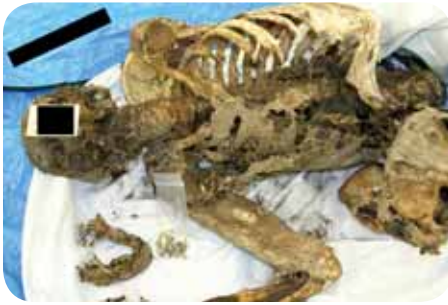

FIGURE 1. Orientation photo, mummified skeletonized human remains.

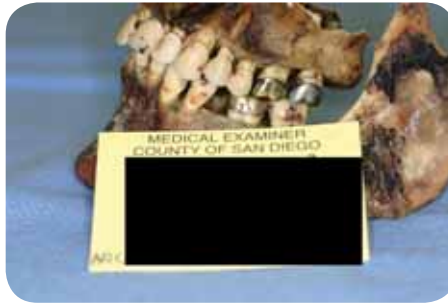

FIGURE 2. Lateral view, resected jaws in occlusion.



FIGURE 3. Level five (cremated) postmortem burned remains.

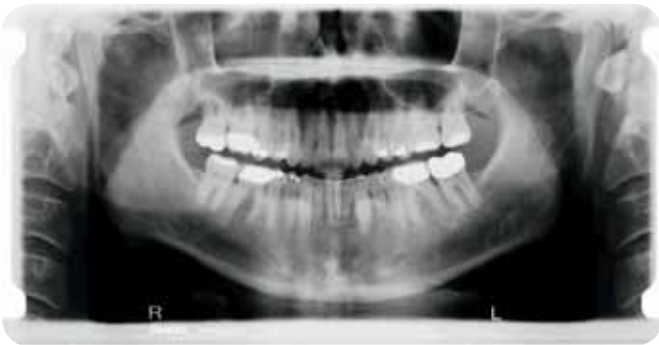

FIGURE 4. Antemortem radiographs.

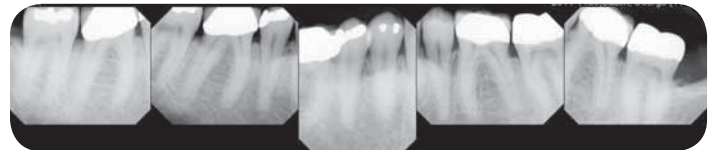


FIGURE 5. Postmortem radiographs.

surrounds a fire and fire suppression efforts. A forensic anthropologist will examine the remains of the skeletal system and can then estimate age, race and sex of the victim. Positive identification is best performed by examination of the surviving dentition. In a fire where the temperatures may be very high (1,000° C) even the dental remains may be destroyed. Crowns may fracture or explode leaving only the roots. Roots may burn leaving only the enamel shell. The bone may also be completely consumed leaving only scattered roots with no bony sockets for reference.

Forensic dental identification is most often accomplished by comparing radiographs of the decedent's teeth (postmortem) with dental radiographs obtained from the dentist of the suspected victim (antemortem) (**FIGURES 4 and 5**). Ideally, the antemortem radiographs should be the original full-mouth series. Often this is not the case. Children's radiographs are typically bitewings only unless they have orthodontic records as well. Often times duplicate radiographs, not the

originals, are sent and have been either poorly duplicated and/or are not labeled right and left for orientation. In addition, the antemortem radiographic image may be of poor quality due to improper operator technique (cone cuts, overlapping interproximals, elongation/foreshortening, etc.) or poor processing (contrast, burned images, etc.). When poor antemortem radiographs are compared to an ideal postmortem radiograph, the two may not appear consistent. This could seriously hamper the identification effort.

In forensic dental identification, we stress that good quality, properly mounted and labeled *original* antemortem radiographs be sent for comparison. In addition, copies of the victim's dental treatment progress notes should be submitted as well. This allows the forensic dentist to verify dental treatment that was performed subsequent to the date of the radiographs. This may then explain the existence of a dental restoration that is not present in the antemortem films or a missing tooth.

Unfortunately, antemortem dental

radiographs are not always available. In California, it is a common misconception that the legal requirement for record retention is seven years when in fact California has no mandatory time interval for retention of records. As a result, when the death investigator contacts the decedent's dentist of record, the records, including the radiographs, are no longer available. This forces the investigator to pursue other options to successfully complete the necessary postmortem identification. When presented with this challenge, the authors have been successful in completing identifications using means other than dental radiographic comparison. The following cases illustrate some of these examples.

The first case is an example of a postmortem identification utilizing dental radiographic comparison to a medical radiograph. The decedent, a 60-year-old white male, was seen in the parking lot of a department store pacing around his vehicle. Minutes later witnesses noted his vehicle engulfed in flames with him sitting in the passenger seat.

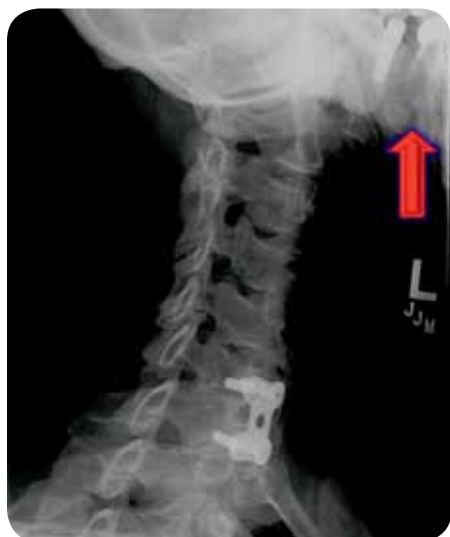

FIGURE 6. Antemortem medical radiograph with mandibular dentition (tooth No. 30, implant at No. 31) visible.

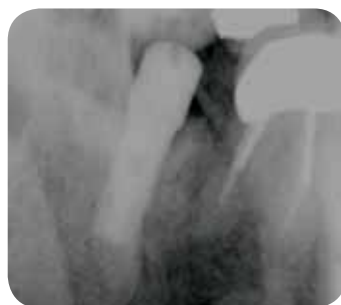

FIGURE 7. Antemortem medical radiograph with dentition cropped and enhanced.

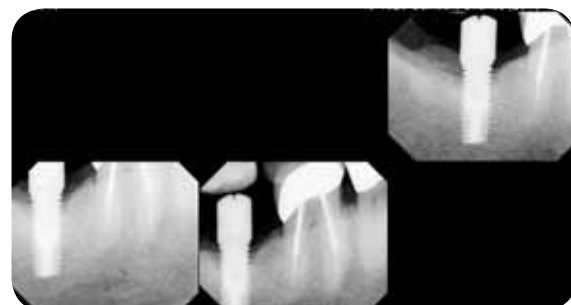


FIGURE 8. Postmortem periapical radiographs (tooth No. 30, implant at No. 31).

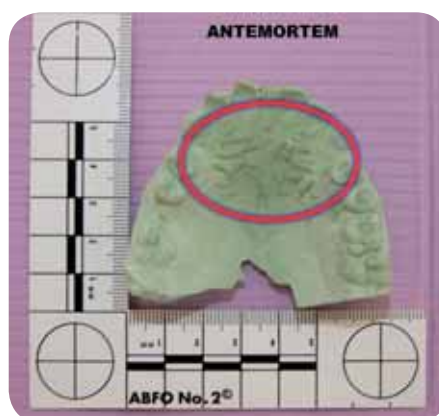

FIGURE 9. Antemortem pretreatment maxillary orthodontic model.

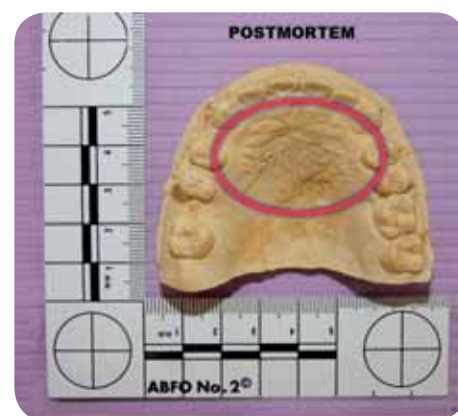

FIGURE 10. Postmortem maxillary model.

Bystanders attempted to extinguish the fire and a 911 call was placed. Emergency personnel responded and confirmed the death without intervention was due to the obvious thermal injuries. A gas can was found in the back seat. The autopsy confirmed the cause of death as inhalation of products of combustion and the manner of death as suicide. The investigator summoned the forensic odontologist to complete a dental identification. Only medical radiographs of the head and neck were available. These radiographs were a frontal and lateral skull series highlighting a medical implant on the cervical vertebra. The dentition was visible on both radiographs but because of the radiographic orientation, the lateral film showed the lower teeth more clearly and with more detail (**FIGURE 6**). Tooth No. 30 (lower-right first molar) was restored with a porcelain-fused-to-metal crown and had an endodontic fill with two posts in both the mesial and distal roots. In addition, tooth No. 31 (lower-right second molar) had been replaced with a dental implant and healing cap but had not

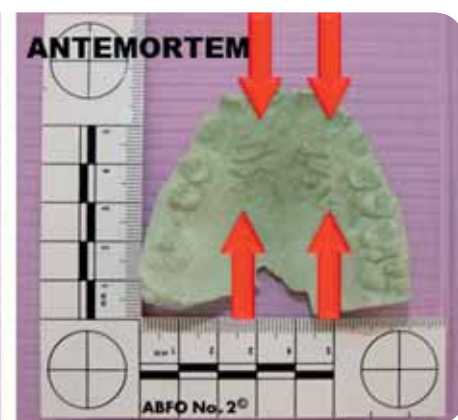
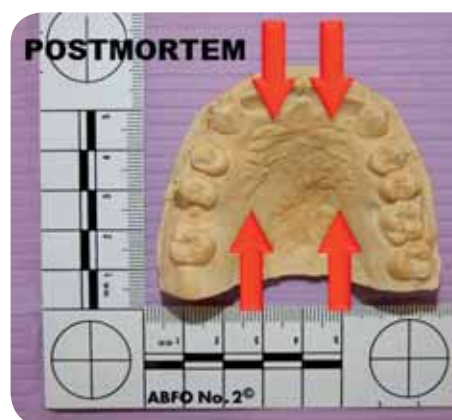

FIGURE 11. Palatal rugae comparison of antemortem to postmortem models.

been restored with a crown. Postmortem dental radiographs were taken and the positive identification was completed based on the comparison of these dental restorations (**FIGURES 7 and 8**).

The next case is an example of identification through the comparison

of palatal rugae. The decedents were involved in a motor vehicle collision. The decedents' SUV was stopped in traffic and rear-ended by an intoxicated driver who was driving home from an impromptu Christmas party. His full-size pickup truck was traveling in excess of 70 mph

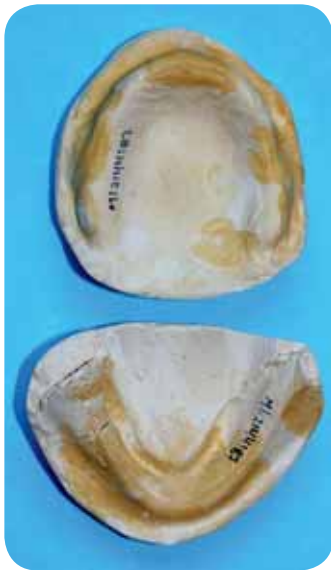

FIGURE 12. Antemortem models of the edentulous mouth.

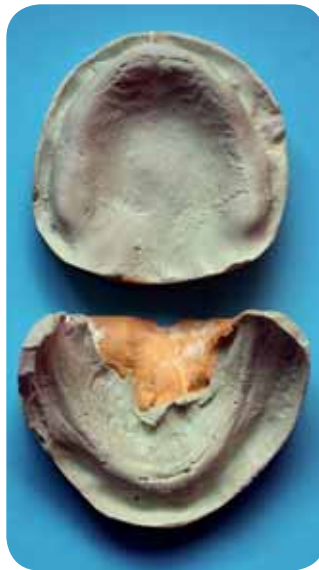

FIGURE 13. Postmortem models of the edentulous mouth.

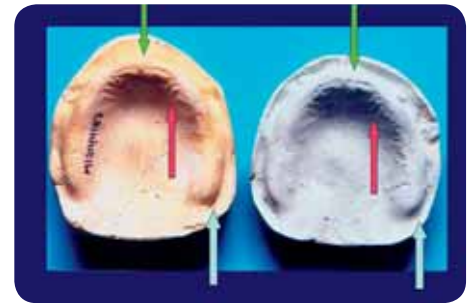


FIGURE 14. Comparison of antemortem to postmortem models.



FIGURE 15. Photographic stand and computer for photographic superimposition.

when it impacted the SUV, causing both vehicles to spin around and then burst into flames. The driver of the truck was able to exit his vehicle unscathed but both occupants of the SUV were killed upon impact. The bodies were charred to a level four postmortem state (burned beyond recognition). Identification by dental record comparison would be necessary. The medical examiner's investigators worked through the weekend procuring the necessary antemortem dental records for postmortem comparison. It was assumed that because the passenger in the SUV was traveling to Tijuana, Mexico, for an orthodontist appointment, adequate dental records would be readily available. Unfortunately, this was not the case. On Monday morning, the investigator discovered that the Mexican orthodontist had not taken pre-orthodontic treatment radiographs of any type. The only pretreatment records the orthodontist possessed were study models. It was decided to obtain the pretreatment models from

the orthodontist in Tijuana for possible postmortem comparison. The driver of the SUV had antemortem dental radiographs available from her dentist in San Diego. The investigator obtained those records and the odontologist completed the dental identification that night.

On the following night, the postmortem dental identification was completed for the passenger. The investigator had obtained the antemortem pretreatment orthodontic models (**FIGURE 9**) and fortunately the postmortem condition of the oral cavity was unaffected by the fire and was sound. The jaws were resected, an alginate impression of the maxilla was taken and a stone model was poured up to be separated at a later time. Once the model was trimmed and finished (**FIGURE 10**) a comparison was made between the antemortem and postmortem models. There were numerous consistencies in the patterns of the rugae and this identification was clearly to the level of positive identification (**FIGURE 11**).

We have commented on the uniqueness of the human dentition and this extends to the edentulous. In this case, an elderly woman died in a fire that consumed her mobile home and burned her beyond visual recognition. During autopsy, it was discovered that she was edentulous and was not wearing dentures at the time of the fire. In many fires involving people who wear dentures, the dentures can survive depending upon the intensity and duration of the fire. California law requires dentists to offer the option to patients of having a denture labeled with an identifying mark such as a name. This label, while not sufficient evidence for a positive identification, can contribute to a preponderance of evidence that allows the coroner or medical examiner to make a judgment as to identification. In this case, there were no dentures. However, the decedent was in the process of having dentures made. Antemortem models of the edentulous mouth were made available for comparison (**FIGURE 12**).

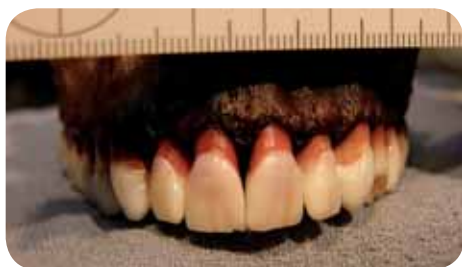

FIGURE 16. Resected maxilla in correct photographic orientation.

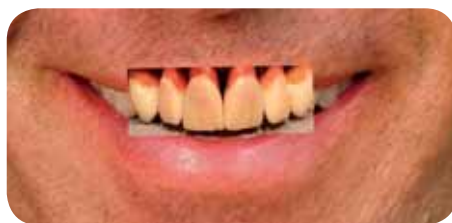

FIGURE 17. Postmortem anterior dentition superimposed onto antemortem photograph (100 percent opacity).

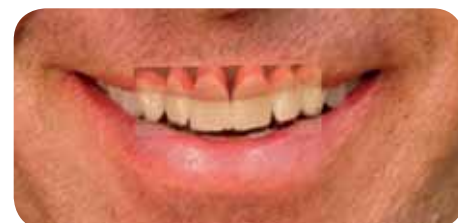

FIGURE 18. Postmortem anterior dentition superimposed onto antemortem photograph (50 percent opacity).

Impressions were made of the edentulous victim using a polyvinyl-siloxane impression material with stock metal denture trays. Stone models were made for comparison (**FIGURE 13**). It became readily apparent that the many anatomical features of the postmortem edentulous mouth compared precisely to the antemortem models allowing for a positive identification (**FIGURE 14**).

If there are no dental records of any type available, photographic superimposition has become another recent option with the advent of analysis using digital photo software. The following case is an example of a dental identification through photographic superimposition of the maxillary anterior dentition.

The body of an adult male who had been missing for approximately one month was found next to his car at the base of a 300-foot ravine. The body was in an advanced state of decomposition and the pathologist requested the identification be completed by dental record comparison. Unfortunately, there were no antemortem dental records of any type available. The investigator discovered that the family had just recently posed for family photographs. These photos were shot by a professional photographer and were readily available. The author obtained the photos and chose the photo that best depicted the maxillary anterior teeth from canine to canine (teeth Nos. 6-11). At the medical examiner's office, the author then resected the maxilla and placed it on a photographic stand alongside a table with a laptop that had the antemortem photograph (**FIGURE 15**). Having the antemortem

photo nearby was crucial when taking the postmortem photo of the resected jaw. This is because the angulation of the photos must be duplicated in the X, Y and Z (depth) axes for the superimposition to be correct and accurate. After shooting numerous photos, the best picture, which captured the correct angles in all three planes, was achieved (**FIGURE 16**).

Next, using Adobe Photoshop digital imaging software, both the antemortem and postmortem images were cropped, resized lifesize 1:1 (actual lifesize) and then the postmortem image was superimposed onto the antemortem image (**FIGURE 17**). This image was faded away in percent increments to reveal the underlying antemortem image. The ideal fade was 50 percent opacity, which allowed both images to appear together and showed multiple consistencies in the dentition (**FIGURE 18**). These multiple consistencies allowed for a confidence level of positive identification.

Occasionally, the thermal damage from a fire has such devastating impact that there is little left of the human body that is recognizable as human tissue. In the early 90s, a 23-year-old woman disappeared from a rural community in Northern California. More than 20 years later, the local sheriff's department was contacted by someone claiming to know where a body had been taken and burned after a homicide. Provided with detailed maps of the area, sheriff's investigators found a small amount of charred material that was recovered for analysis. The body had been burned along with rubbish and the fire had burned for a very long time. The recovered material

was very fragile and powdery; it crumbled when manipulated (**FIGURE 19**). Amongst this material were the enamel crowns of teeth and some associated dental amalgam restorations. Relying on basic dental anatomy it was possible to determine that the dentition was from a single individual (**FIGURE 20**). Antemortem dental X-rays were available from the possible decedent, but were of poor quality and a significant amount of dental work had been performed after the films were made. Without the ability to orient the teeth in an arch as they might appear in the mouth, a large number of radiographs from varying angles were made of individual enamel crowns for comparison. While the overall evidence indicated that the identification could be considered possible, and that the decedent could not be eliminated from consideration, a single enamel shell and its associated amalgam restoration became the subject of further scrutiny. After more than 20 exposures, an angle was duplicated that allowed for a positive identification based upon the unique characteristics of the amalgam restoration (**FIGURE 21**). The person providing the tip was a juvenile at the time of the murder. His father murdered the young woman and forced his son to help him dispose of the body. The tipster feared for his own safety and waited until his father had died before leading authorities to the remains.

The uniqueness of dental restorations can be as critical as the uniqueness of the dentition as illustrated by the above case and the one that we will now describe. In 2013, a badly decomposed body was recovered along the Marin coast, north



FIGURE 19. Human cremated remains.



FIGURE 20. Collection of dental evidence from cremains.

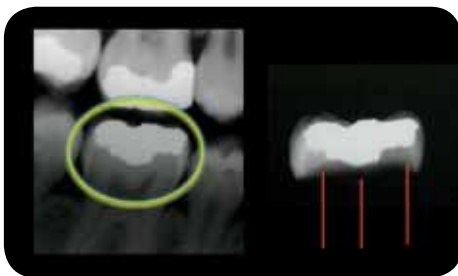

FIGURE 21. Antemortem to postmortem comparison of amalgam restoration.



FIGURE 22. Gold "filling" (onlay) recovered in decedent's home.

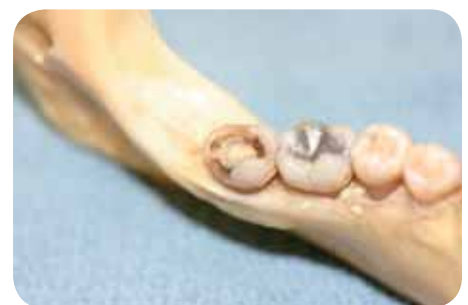

FIGURE 23. Postmortem mandible showing tooth No. 18 with missing restoration.

of the Golden Gate Bridge. There have been more than 1,600 confirmed suicide victims who have jumped from the bridge since it opened in 1937. It is very likely that there are more victims who were not witnessed or otherwise confirmed as having jumped as well.

Personal effects and the circumstances of discovery of this body were such that investigators were able to find a possible missing person that warranted further investigation. In this case, family and friends had no information that could lead to dental records. Interviews with family and friends led to the discovery of a gold filling that had fallen out and was saved in a plastic bag in the decedent's apartment (**FIGURE 22**).

Examination and comparison to the remains showed that tooth No. 18 (lower-left second molar) had what appeared to be a lost onlay (**FIGURE 23**). When compared to the gold filling, it was immediately obvious that the restoration fit the tooth extremely well and because of the nature of the restoration it was highly unlikely that it could be associated to another individual (**FIGURES 24 and 25**). In this case, the positive association of the onlay to the tooth was not in and

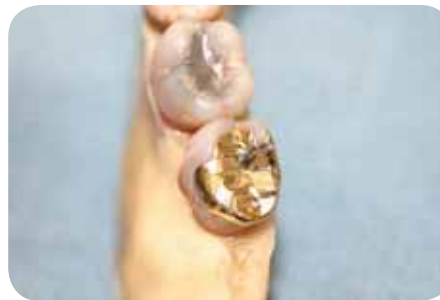

FIGURE 24. Postmortem mandible showing gold onlay seated in place on tooth No. 18.

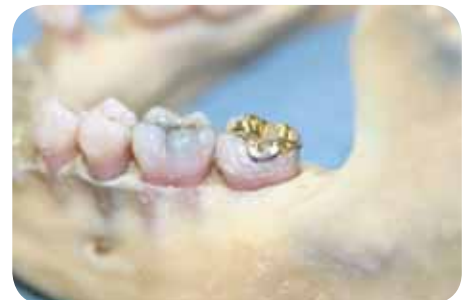

FIGURE 25. Postmortem mandible showing gold onlay seated in place on tooth No. 18.

of itself a definitive identification because there was no antemortem trail of evidence to confirm the source. The identification was determined by the coroner on the preponderance of evidence in the case and in essence, the onlay was considered a personal effect by investigators.

Conclusions

While traditional dental identifications made by comparisons of antemortem and postmortem radiographic evidence account for the vast majority of identifications, unique details of the dentition captured in other ways can lead to positive identifications. Dentists

should be aware that even details that may seem insignificant at first could prove to be a critical clue in the identity of an individual. Therefore, it is prudent to thoroughly document the existing conditions of new patients and subsequent dental work. It is critical that the entire original documentation be submitted to authorities when requested. In conclusion, it is important to remember that patient privacy restrictions do not apply when a person is deceased and authorities request a decedent's dental records. ■

THE CORRESPONDING AUTHOR, Anthony R. Cardoza, DDS, can be reached at rickandkimm@cox.net.



Bite-Mark and Pattern Injury Analysis: A Brief Status Overview

Gregory S. Golden, DDS, DABFO

ABSTRACT Bite marks are one component of forensic investigation requiring subjective interpretation for determining unknown source evidence to a putative suspect. Recent scrutiny has lead to questions about the scientific validity of patterned evidence, bite-mark analysis in particular, and its role in judicial proceedings. This article discusses some issues that persist in forensic circles and the difficulties surrounding the field of bite-mark analysis that inherently must employ human subjectivity in its execution of duty.

AUTHOR

Gregory S. Golden, DDS, DABFO, received his dental degree from the Herman Ostrow School of Dentistry of the University of Southern California in 1975. He became a diplomate of the American Board of Forensic Odontology (ABFO) in 1982. In 1992, he became the chief odontologist for San Bernardino County and continues to serve several Southern California counties as a forensic consultant. He is a co-director of CDA's Committee on Mass Disasters and the southern regional director for the California Dental Identification Team.
Conflict of Interest
Disclosure: None reported.

To say that bite-mark analysis has taken its rightful place in the history of forensic investigation would be an unwise statement. Little did the Texas Court of Criminal Appeals realize in 1954 (*Texas v. Doyle*) the impact a peek into Pandora's box would have on the world's judicial system of finding truth for the trier of fact when general dentist William Kemp tied suspect James Doyle's teeth to a bite in a piece of cheese left at the scene of a grocery store burglary. Twenty-one years later the box was fully pried opened on the admissibility of bite-mark evidence in *People v. Marx* (Court of Appeals of California, Second Appellate District, Division Five, Dec. 29, 1975), wherein three odontologists testified that they could see similarities between

the teeth of defendant Walter Edgar Marx and a three-dimensional bite on the nose of 75-year-old homicide victim Lovey Benovsky. Marx was convicted of voluntary manslaughter partly as a result of the weight of the bite-mark evidence, thereby setting the standard for cases involving bite marks as evidence. In 1989, Theodore "Ted" Bundy, a self-proclaimed serial killer, was executed. While normally a master at removing incriminating evidence from his victims, Bundy left a bite mark on the body of Lisa Levy, a Florida State University sorority coed. Several experts testified about that bite mark during his trial, thereby reaffirming the value of bite pattern injuries on human skin committed during violent crimes.

Much has happened since then. Bite-mark evidence has been accepted during trials in every one of the United

States.¹ With the acceptance of bite-mark evidence as part of the judicial process, hundreds of trials have given credence to a diagnostic procedure that the scientific community has accepted, even embraced, until recently. The emerging notoriety and recognition of bite-mark evidence brought to the field of forensic dentistry and its participants was somewhat premature, in that the opinions of some of its more enthusiastic members in their efforts for “due diligence” overstepped their abilities to accurately interpret what they were examining, much less exercise sound judgment regarding their opinions. As a result of a desire to “do the right thing” on the part of a few forensic dentists, coupled with bungled police work, misidentification from mistaken or bought eyewitnesses, coerced false confessions, tunnel-vision by investigators, unethical or incompetent lawyers, uninformed judges and phony science, the most unspeakable of outcomes occurred. Innocent people were sentenced to prison. Some 30 to 40 years after the innocent person had been vindicated and the true perpetrator identified, a review of how the damage was undone is varied, including all those reasons listed above for the original convictions plus more. Louise Robbins, a footprint expert whose self-proclaimed forensic abilities included her apparent talent to match a footprint on any surface to the person who made it, appeared in more than 20 criminal cases over a 10-year period. Her claims were vehemently contested and were ultimately debunked. Other lab analysts purposely falsified test results and their subsequent testimony to manipulate the trial outcome. Once exposed, they immediately lost credibility.

In light of the historic blunders and the technological advances in forensic investigation since those earlier years, one might argue that that was then, this is now. Largely that is true. Forensic science has a much better Occam’s razor to deal with the solutions of proving guilt or innocence now that DNA profiling has come to fruition. Before DNA typing and the evolution of improved photographic and analytical techniques for tool marks, hair, handwriting, etc., investigators were limited by their own amount of experience and their ability to

Forensic science has a much better Occam’s razor to deal with the solutions of proving guilt or innocence now that DNA profiling has come to fruition.

interpret accurate pattern recognition. As for bite-mark injuries, considering that the majority of them are evaluated from an elastic medium such as human skin and are typically delivered under dynamic, variable conditions, one would expect to see certain inherent distortions in the victim’s injury. This hypothesis has proven itself true. One would think that information alone would persuade forensic odontologists to use extreme caution when attempting to identify the perpetrator of a bite-mark injury, particularly when their opinion may cause a significant impact on an individual’s freedom. It is with these thoughts in mind that this author will attempt to describe the current state of bite-mark evidence and analysis and explain where it is headed.

Pros and Cons

There are currently two factions with strong and equally opposing positions regarding bite-mark evidence. Those who support bite-mark evidence are dedicated to further research and its continued judicious application, and they acknowledge its subjective limitations. Most people in this group consist of forensic dentists and prosecuting attorneys, however, there is at least one defense attorney who is also concerned about the dominance of the current innocence movement.² The forensic experts have a unified goal — to improve their respective fields by conforming to the rules of scientific investigation and to minimize bias from the subjective elements inherent in the process. The skeptics who arrogantly oppose bite-mark evidence, specifically the Innocence Project (IP), target bite-mark analysis within an extensive laundry list of those other troubling areas of forensic science. They consider all human-based, subjective pattern comparisons to be unreliable, and bite-mark evidence in particular is, as one of their loudest criers says, “... the poster child of unreliable forensic science.”³ Not surprisingly, the IP dislikes all forensic odontologists who engage in bite-mark analysis, and especially those who have rigorously achieved board-certified status from the most respected credentialing organization that exists, the American Board of Forensic Odontology (ABOF).

Everyone in both factions recognizes that there have been errors committed, so far in what has amounted to a small fraction of the total number of the hundreds of cases adjudicated throughout the U.S. courts wherein bite-mark evidence has been admitted into testimony. The IP has focused on two dozen exoneration cases wherein it describes bite-mark evidence played

a part in the conviction of an innocent person. A closer look into those cases shows that only 10 of them were reversed from DNA evidence, and not all of them had DNA collected from the bites.⁴ Additionally, in those cited cases where bite-mark evidence was present, the reversals came from various means other than DNA from the actual bite. Interestingly enough, if one were to look deeper into those reversals one would find that many of the errors were committed by the same handful of so-called “experts,” most if not all who have ceased analyzing bite-mark cases in recognition of their own limitations.

One must also consider while there are no solid statistics, law enforcement case files are filled with scores of instances where bite-mark evidence has led to children, who would have otherwise ended up dead, being removed from an abusive environment. In this author’s 35 years of forensic work, numerous cases with crucial bite-mark evidence helped bring closure to friends, families and relatives of victims of abuse, rape and homicide. In similar cases, countless hours of court time and taxpayer dollars have been saved by defendants’ plea bargaining rather than going to trial once confronted with incriminating bite-mark evidence.

Interestingly enough, when enlisted for assistance by the IP, several odontologists certified by the ABFO (this author included), have willingly aided it in seeking freedom for the wrongly convicted in an effort to right those judicial travesties. And we did so pro bono. Knowing this fact one might ask, if lawyers who work for the IP are so vehemently opposed to

allowing bite-mark evidence in judicial proceedings, why then do they feel it is necessary to ask members of the same targeted organization of experts to assist them in the exonerations of those wrongly convicted defendants? On the surface, it would appear that those hostile to bite-mark evidence, such as one IP attorney who refers to the admission of bite-mark evidence in the case of *NY v. Dean* as “... a victory for the flat-earth society,”⁵ and a former but now resigned ABFO diplomate and prolific blogger who refers to bite-mark

In this author’s 35 years of forensic work, numerous cases with crucial bite-mark evidence helped bring closure to friends, families and relatives of victims of abuse, rape and homicide.

experts as “skin readers,”⁶ would never invite board certified experts from the same organization they attack to assist them with their agenda. Yet they have. To be fair, one lone director of the IP recently stated, “Just because the science has been abused doesn’t mean it doesn’t have value. That’s not to say that odontology is impossible. There are some strong conclusions that can be drawn from odontology and bite marks specifically. It’s just like any tool; you have to know how to use it properly.”⁷

While the IP’s cause is noble, a deeper look into its motivation for righting the miscarriages of justice is required.

Many of the wrongly convicted, once exonerated, are urged to civilly sue the expert dentist(s), the agencies and jurisdictions that put them behind bars. The IP most likely takes its fair share of these generous financial awards.

As unrealistic as this may sound, a more unified and constructive approach might be to have the IP and forensic experts work together toward the goal of improving the mechanism for interpretation of scientific evidence rather than perpetuate what to date has been a one-sided vitriolic portfolio of invectives. The source of the hate-speak emanates from a collection of media wonks who put the negative spin on bite-mark evidence,^{8,9} often misinforming readers with inaccurate reporting of the entirety of the factual details of the case, never mentioning those cases wherein bite-mark evidence was crucial to an accurate judicial outcome or saving of a life. The conflict continues to wage on. Most recently, the *Washington Post* chimed in with a four-part lambasting of bite-mark experts and the notorious cases, most that occurred decades ago.⁸ Ultimately, decisions regarding the admission of bite-mark evidence have been, and most likely will be, determined in each case by the Frye* and Daubert standards and the decision will land squarely in the hands of the courts, because judges are the final gatekeepers of admission of this type of evidence.

The NAS Report

In February 2009, the National Academy of Sciences (NAS) issued its report, *Strengthening Forensic Science in the United States: A Path Forward*,¹¹ as

*The Frye standard, Frye test, or general acceptance test is a test to determine the admissibility of scientific evidence. It provides that expert opinion based on a scientific technique is admissible only where the technique is generally accepted as reliable in the relevant scientific community. In *Daubert v. Merrell Dow Pharmaceuticals*, 509 U.S. 579 (1993), the Supreme Court held that the Federal Rules of Evidence superseded Frye as the standard for admissibility of expert evidence in federal courts. (caselaw.lp.findlaw.com/scripts/getcase.pl?court=US&vol=509&invol=579) Some states, however, still adhere to the Frye standard.⁹

a blanket government mandate for all forensic investigators to conform to the scientific community at large, and to adapt to accepted scientific principles and associated research. Since its publication, there have been varied interpretations by members of the same forensic community of not only exactly what the NAS report actually said, but what it meant for them. Either way, the fall-out was felt in every corner of forensic investigative fields and for now it seems to have forensic scientists productively working toward those intended goals. In 2013, the National Institute on Standards and Technology (NIST) developed several Organization of Scientific Area Committees (OSAC) working in conjunction with the National Department of Justice to strengthen forensic science in the U.S. Members of these committees and subcommittees represent leaders in the fields of DNA analysis, chemistry/instrumental analysis, IT/multimedia evidence, crime scene/death investigation, physics/pattern analysis, even forensic odontology. Information on these teams and their specific areas of scientific investigation can be found at nist.gov/forensics/osac/index.cfm.

The Research

Prior to the NAS recommendations, several research projects in odontology had been conducted to determine important issues relating to the accuracy of bite-mark pattern injuries, such as the uniqueness of human dentition^{12,13} and the amount of distortion in skin during the act of biting.¹⁴ Results from those studies have so far proven that more and better-designed research is needed. Questions regarding the inherent limitations of several of these studies were glaringly focused, in that the predominance of that research was conducted on human cadavers

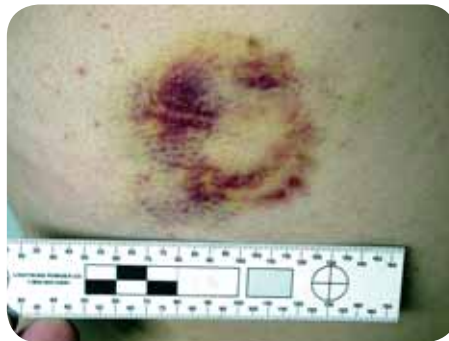


FIGURE 1. A pattern “suggestive of a bite mark” on the abdomen of a rape victim. Low evidentiary quality, no analysis required.

and anesthetized pigs. Needless to say, controlled, long-duration biting of a refrigerated cadaver with a pair of vice-grip-mounted study casts, (sometimes having maxillary and mandibular models from two people) will produce totally different data results than research conducted on living people. As useful as this research has been, bites on cadavers and anesthetized pigs can be manipulated to produce distorted or nondistorted patterned injuries. Depending on what results the researchers want to end up with determines how the bites are made. One would expect that research on living subjects would produce even more distorted bites. And therein lays just one part of the problem. Locating live volunteers who are willing to participate in bite-mark research studies can be like searching for a kid who wants a tetanus shot. Indeed, those who have volunteered have made some interesting, nonsupportive vocalizations while being bitten at 90-100 pounds per square inch (PSI) under controlled conditions. And as expected, the delivered bites contain varied amounts of distortion, size and appearance. What the data from these live-subject tests have given researchers is valuable insight into exactly how much pressure is required to deliver a sustainable bruise, and even more profoundly, the inflicted pain victims must experience during violent criminal activity. Nevertheless, scientific research

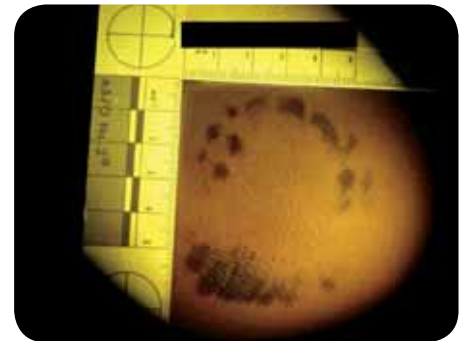


FIGURE 2. An adult dentition bite mark on the shoulder of a female victim of a homicide. Dental arches and individual tooth markings are identifiable. High evidentiary quality, analysis should be initiated.

must proceed. The NAS said so, but there are conditions to be met first.

Research on living subjects must comply with rules established by certain organizations such as the Institutional Review Board (IRB), a committee that assures in advance and by periodic review that appropriate steps are taken to protect the rights and welfare of humans participating as subjects in these research studies. Complicating the process are other agencies such as the National Institutes of Health (NIH), the Forensic Science Education Programs Accreditation Commission (FEPAC), NIST, NAS and the National Research Council (NRC), to name but a few. Each of these agencies has an active role in authorizing, controlling and validating certain areas of scientific research and accreditation. This is not to say future research in bite-mark analysis on living humans is on a dead-end street. Quite the opposite is true. One recent scientific presentation¹⁵ and future research projects are currently being designed to address these ethical issues so that more realistic and scientifically valid data can be accumulated to answer the questions of the uniqueness of teeth and their reliability for accurately transferring an individual's dental signature to living human skin under controlled conditions.

Most promising is the research on collection of salivary DNA from bite marks.¹⁶ DNA evidence always trumps subjective interpretation or opinions by

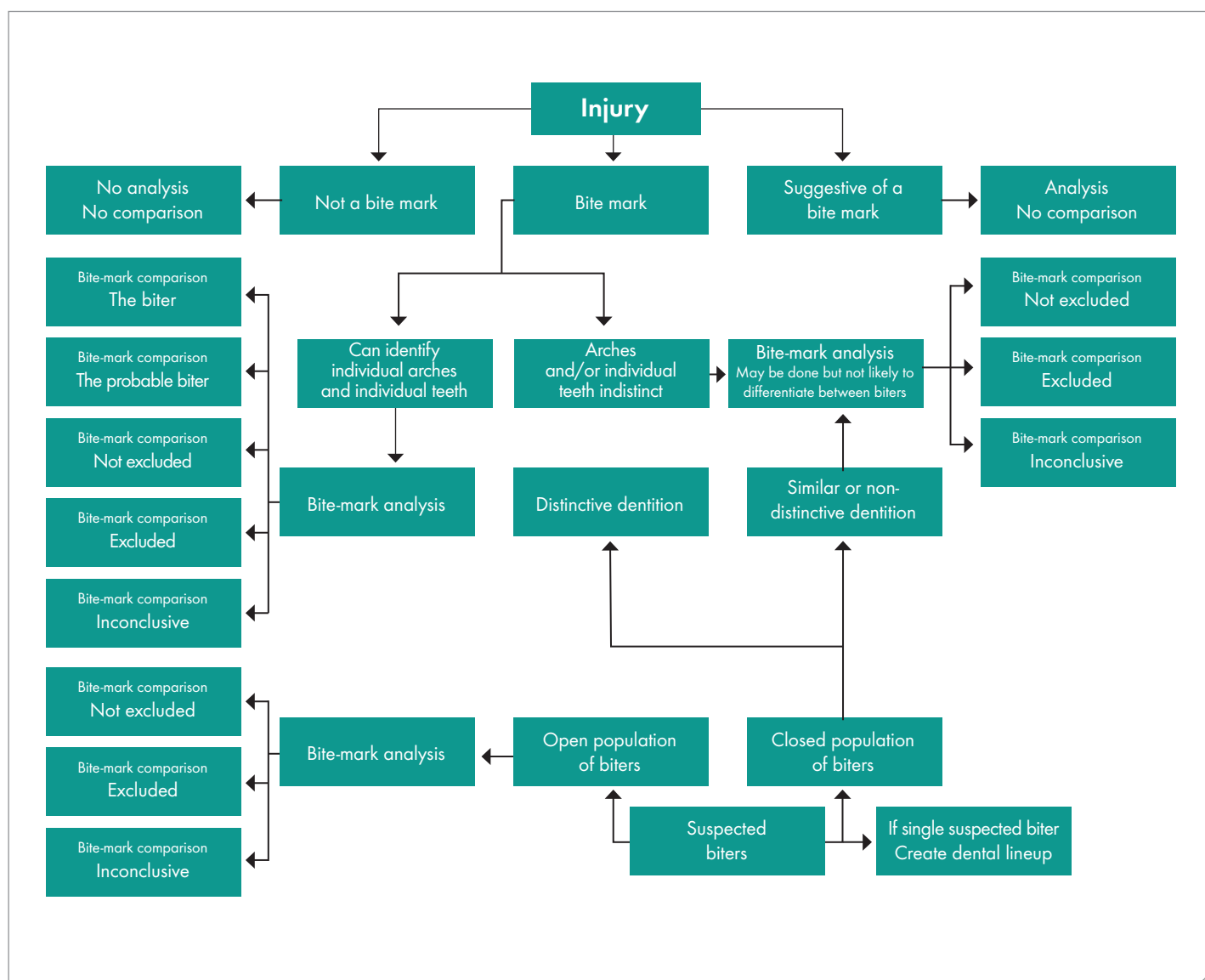


FIGURE 3. The ABFO flow chart (2013).

experts in any pattern injury analysis, which is precisely why the current standard operating procedure for bite-mark investigation is to swab the bite for DNA first, before doing anything else.¹⁷ Another promising tool currently under development by the ABFO is bite-mark proficiency testing.¹⁸ Testing an expert's ability to be a "skin reader" may raise a few eyebrows, but if designed properly, in the long run it should have a positive influence on the discipline.

Meeting the Evidentiary Threshold

There are several requirements to be met before a bite mark should be considered for analysis. The first consideration is that the questioned bruise is, in fact, identifiable as a bite. The source can be from an animal or human. Because forensic dentists routinely see pattern injuries that mimic bite marks, anything "suggestive of" or "not a bite" requires no analysis or comparison. FIGURE 1 is a bruise pattern

on the abdomen of a rape victim that does not meet the threshold of useful evidence or the definition of a bite mark.¹⁹ Although it is round and appears to have been made by teeth, there are no individualizing characteristics revealing tooth size or position evident in the bruise. Once a bruise pattern meets the criteria for being an actual bite mark, the second level to consider before proceeding with analysis addresses the quality of the bite mark.

The more individual characteristics there are visible to the observer (i.e., separate and distinct arches, identifiable tooth marks, etc.), the more likely the pattern injury will be useful as evidence (**FIGURE 2**). **FIGURE 2** represents a human adult bite on the shoulder of a homicide victim. Maxillary and mandibular arches can be determined, as well as the individual teeth present in both arches. A third consideration is the population of suspected biters. A defined population is one in which there are a limited number of suspects, usually targeted by law enforcement, social services or health care providers. The more differences there are between the suspect's alignment and number of teeth, the more likely the actual suspected biter can be identified. An undefined population presents a greater problem in that there is no limit to the number of suspected biters. These prerequisites drive the analytical process and are necessary steps for the investigating odontologist to evaluate prior to the analysis and comparison of putative suspected biters before developing conclusions or linkage to them.

FIGURE 3 represents the initial version of the ABFO bite-mark analysis flowchart. Since its acceptance, and due to recent validation studies done by the ABFO, acknowledgment that a more refined and scientifically verifiable version is necessary. The next version will have significant changes that should minimize interexaminer error. In the meanwhile, odontologists are encouraged to follow the current flowchart from the top down. Doing so provides critical decision points for directing the investigating odontologist in a scientific and logical step-by-step path toward accuracy. For now, regardless of one's practical experience, bite-mark analysts

should utilize the current version of the flowchart to its best advantage. And, as a secondary fail-safe measure, the ABFO now mandates that the primary investigator seek additional methods and conclusion corroboration by independent analyses from other equally qualified or more experienced experts. The review is done blind, without the other experts knowing any details of who the suspected biter(s) is or other circumstances of the case.

To summarize, forensic investigators tasked with the specific fields of pattern analysis realize that in the short run there will be limitations on the acceptance of their opinions in court because their evaluations have, by nature, a subjective component. With the exception of automated fingerprint identification, the development of nonbiased computer analysis of latent patterned evidence is relatively still in its infancy. Whether or not scientifically based devices and testing methods are developed that serve to brace the underpinnings of bite-mark analysis will determine its lifespan in the future, and whether or not it will continue to be accepted in courts. For the most part, it would appear that in spite of previous mistakes, the research is heading in the right direction. The scientific evolution of man's knowledge is always a work in progress. ■

REFERENCES

1. Pretty IA, Sweet DJ. The Judicial View of Bite Marks Within the United States Criminal Justice System. *J Forensic Odontostomatol* vol. 24, no. 1, June 2006.
2. Smith A. In Praise of the Guilty Project: A Criminal Defense Lawyer's Growing Anxiety About Innocence Projects. Georgetown University Law Center, 2010 scholarship.law.georgetown.edu/facpub/876.
3. www.innocenceproject.org/news-events-exonerations/bite-mark-evidence-deemed-unreliable.
4. www.law.umich.edu/special/exoneration/Pages/about.aspx.
5. <http://wrongfulconvictionsblog.org/2013/09/06/a-victory-for-the-flat-earth-society>.
6. [bitemarks.org/2011/03/30/the-inane-responses-of-](http://bitemarks.org/2011/03/30/the-inane-responses-of-dentists-who-describe-themselves-as-%E2%80%9Cskin-reading%E2%80%9D-experts)

- [dentists-who-describe-themselves-as-%E2%80%9Cskin-reading%E2%80%9D-experts](http://bitemarks.org/2011/03/30/the-inane-responses-of-dentists-who-describe-themselves-as-%E2%80%9Cskin-reading%E2%80%9D-experts).
7. Simpson A. Director, California Innocence Project.
8. www.washingtonpost.com/news/the-watch/wp/2015/02/13/how-the-flawed-science-of-bite-mark-analysis-has-sent-innocent-people-to-jail.
9. news.yahoo.com/ap-impact-bites-deided-unreliable-court-150004412.html.
10. en.wikipedia.org/wiki/Frye_standard.
11. www.nap.edu/openbook.php?record_id=12589.
12. Miller R, et al. Uniqueness of the Dentition as Impressed in Human Skin: A Cadaver Model. *J Forensic Sci* 2009; 54 (3): 909-14.
13. Kieser JA, et al. The uniqueness of the human anterior dentition: a geometric morphometric analysis. *J Forensic Sci* 2007; 52 (3): 671-7.
14. Bush M, et al. Biomechanical Factors in Human Dermal Bitemarks in a Cadaver Model. *J Forensic Sci*, 2009; 54 (1): 167-76.
15. Senn D, et al. High-Speed Videography of Simulated Human Bites on the Skin of Living Humans. AAFS Scientific Session, Odontology Section, 2014.
16. Sweet DJ, et al. An improved method to recover saliva from human skin: The double swab technique. *J Forensic Sci* 42:320-322.
17. ABFO Reference Manual, January 2015.
18. Minutes from ABFO Bitemark Committee meeting. February 2014, in conjunction with Occupational Research Associates Inc.
19. ABFO Reference Manual, January 2015.

THE AUTHOR, Gregory S. Golden, DDS, can be reached at medich@aol.com.



Forensic Dental Age Estimation: An Overview

James M. Lewis, DMD, DABFO, and David R. Senn, DDS, DABFO

ABSTRACT Forensic age estimation is a scientific process that estimates an individual's true chronologic age by assessing skeletal and dental development and maturation. Although human growth and maturation is unique to each individual, dental techniques for estimating age are currently considered the best in assessing true chronologic age particularly during the age range when the dentition is undergoing morphologic development. This article reviews the principles, methodology and commonly used techniques in forensic age estimation cases.

AUTHORS

James M. Lewis, DMD, DABFO, is a forensic dental consultant for the state of Alabama, a fellow of the American Academy of Forensic Sciences and the age estimation committee chair of the American Board of Forensic Odontology.
Conflict of Interest
Disclosure: None reported.

David R. Senn, DDS, DABFO, is the director of the Center for Education and Research in Forensics at the University of Texas Health Science Center at San Antonio. He is a fellow of the American Academy of Forensic Sciences and past president of the American Board of Forensic Odontology.
Conflict of Interest
Disclosure: None reported.

Although the first recorded use of dental age estimation is attributed to the Romans for use in assessment of age for military conscription, scientific rationale was not applied to dental age estimation until child labor laws of the early 1800s prompted a legal interest in assessing the true chronologic age of children.^{1,2} Forensic age estimation has many possible applications in modern society. It can significantly aid the process of identifying missing and unidentified individuals through estimation of the age at death; differentiate clustered victims in mass disasters; aid immigration service in the processing of undocumented immigrants; help to determine eligibility of social benefits and questions of age of license; and assist the legal system regarding criminal and civil matters involving questions of legal majority.

Age estimation theory can be categorized into three basic scientific rationales: formation and growth changes, postformation and maturation changes and biochemical changes.

Regardless of which scientific rationale is employed in the assessment of age, its scientific basis can be explained mathematically by the normal distribution curve, also known as a bell curve. Morphologic development, histologic and anatomic postformation changes, and biochemical changes of the dentition conform to a process of random variation whereby these events generally occur within a given time interval or age range. At any given stage of development or maturational change, the statistical results will cluster about the mean. There will always be individuals described as outliers. These outliers will decrease in frequency the further they are removed from the mean, and the results will occur symmetrically. The measure of variability and risk of a

TABLE 1

Comparison of Two Age Estimation of Children Techniques

	Demirjian et al.	Moorrees et al.
Age range (where useful)	Approximate age 3–14 years	Birth to maturity
Weight assigned to each tooth	Equal	Individual
Error rate	80 percent confidence	95 percent confidence
Population studies	Multiple	Few
Limitations	Fragmented cases and missing teeth	Low number of population studies

TABLE 2

Adult Variable Checklist

Variables	Kvaal	Maples	Lamendin	Prince/ Ubelaker	Bang and Ramm	Cameriere 2004	Cameriere 2007
Root translucency (intact)			✓	✓	✓		
Root translucency (sectioned)		✓			✓		
Secondary dentin		✓					
Periodontal recession			✓	✓			
Root length			✓	✓			
Radiograph	✓*					✓*	✓**

*Radiographs taken from labio-lingual direction.

**Radiographs taken from both labio-lingual and mesio-distal directions.

normal distribution curve is defined by another mathematical expression unique to each individual curve, its standard deviation. This allows the forensic investigator to not only provide authorities with an assessment of the estimated age of an individual, but also to provide a statistical range of age possibilities.³

Formation and Growth

Techniques that utilize tooth formation and growth changes assist in the age estimation of infants, children and adolescents. Tooth formation and growth can be subdivided into progressive morphological changes describing development of the tooth's crown, root and apex, and eruption sequence of the dentition. It should be noted that eruption pattern techniques are less accurate compared to methods considering morphological development of teeth.³

Age Estimation Charts

The age estimation charts were developed through analysis of the remains of various skeletal collections.^{4,5} These charts consider neither the ancestral origin nor the gender of an individual when utilized in age assessment. When accuracy is paramount, it is crucial to utilize radiographic age assessment techniques that consider genetic factors (ancestry and gender). Extreme environmental factors may also affect the growth and development of the dentition and should be considered. Environmental factors may include nutrition, disease, treatment of disease, habits, addictions and place of residence.⁶ Therefore, when possible, the statistical data from the most closely associated population study to the individual in question should be used.

Radiographic Techniques

The Moorrees et al.,^{7,9} Demirjian et al.^{9,10} and Mincer et al.¹¹ radiographic techniques require the staging of the teeth based upon a tooth's degree of morphological development. When using any of these methods, teeth that are malformed or have any associated pathology should not be considered in the age assessment process. Moorrees et al. and Demirjian et al. techniques assist in the age estimation of children. The Moorrees technique describes 14 stages of tooth development and allows for age assessment utilizing individual teeth, while the Demirjian technique requires the staging of all seven teeth on the mandibular left side using an eight-stage system. **TABLE 1** compares and contrasts the differences between the Demirjian and Moorrees techniques.

In social benefit cases and cases of legal age of majority, age is most commonly assessed using the Mincer et al. technique staging third molar development. For each stage of development, these studies publish statistical data on estimated age, standard deviation and probability of attaining age 18. Knowing the probability of the attainment of age 18 is most beneficial in immigration cases. However, in other cases of legal age of majority, the probability of attaining any other age in question must be hand calculated. Key factors in these types of estimation of age cases include:

- Consideration of all teeth in the dentition.⁸
- Consideration of gender and environmental factors.⁶
- Use of the best ancestral population-specific study available.¹²
- Consideration of the effects of ancestral admixture.¹³
- Utilization of multiple technique modalities for age estimation, including anthropologic methodology.^{3,6}

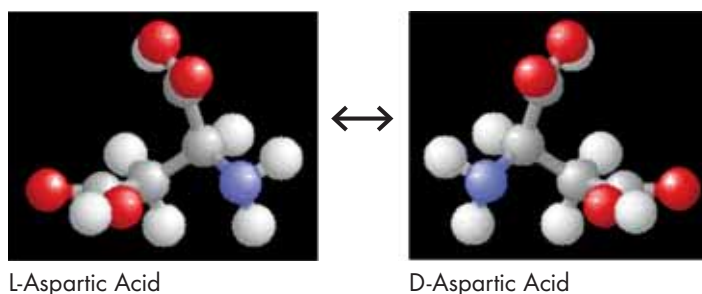


FIGURE 1. Racemization of aspartic acid.

Postformation and Maturation Changes

Once all osseous and dental growth and development has ceased, postformation and maturation changes are all that remain to assess age. The six classic postformation and maturation changes that occur in teeth are attrition, periodontal disease sequelae, secondary dentin formation, cementum apposition, root transparency and root resorption. It is well-documented that root resorption is the poorest of these indicators of chronologic age. Most of the early researchers in dental age estimation concluded that the ranking of the efficacy of postformation criteria that correlate age from best to worst is root translucency, secondary dentin formation, attrition, gingival recession and cementum apposition.¹⁴ However, there is some very recent research in the use of cementum annulations as an indicator of age that may prove very useful in age assessment.¹⁵ Cementum annuli are the concentric rings that can be seen within dental cementum upon viewing a cross section of the tooth root. These rings represent the annual and cyclic deposition of dental cementum in mammals.

Accurate adult dental age estimation necessitates careful tooth and technique selection based upon the dental material available for analysis and any external factors that may affect postformation criteria. The effect of ancestry and gender is minimal on the progression of root translucency and secondary dentin deposition. However, dental

restorative therapy, endodontic and orthodontic treatment, trauma, decay, pathology, hyperocclusion and lack of an opposing dentition can affect some or all of the postformation criteria with the exception of root translucency.¹⁶

Popular adult dental age estimation techniques, including the Bang and Ramm,¹⁷ Maples (particularly the S and T formulas),¹⁴ Lamendin, et al.,¹⁸ Prince and Ubelaker,¹⁹ Kvaal et al.²⁰ and Cameriere et al.,^{21,22} all require destruction or sacrifice of dental tissue with exception of the Kvaal et al. and the Cameriere et al. techniques. The Kvaal and Cameriere techniques assess the radiographic tooth pulp volume from the labiolingual aspect to estimate age. Therefore, these are the only adult age estimation techniques ethical for use in the living. **TABLE 2** contains the criteria required to perform the techniques listed above.

Biochemical Changes

The advantages of biochemical age estimation techniques are that they may be used in any age group and offer a high degree of accuracy. Disadvantages include time, expense and the sacrifice of tooth structure.

Amino Acid Racemization

All living organisms utilize proteins as the basic building block of their biologic composition. Structurally, these proteins are comprised of amino acid sequences. All amino acids (except glycine) have two asymmetrical geometric forms that are mirror images of one another and are

known as stereoisomers designated as “L” and “D” forms of the molecule. At birth, only the L form of the amino acid molecule exists systemically. Racemization is the gradual and spontaneous process of a stereoisomer pure solution converting to a mixture of equal amounts of the L and D stereoisomers (**FIGURE 1**). Racemization begins immediately at birth.

Age can be estimated by measuring the degree of racemization that has occurred in a metabolically inactive tissue.²³ Tooth dentin is rich in aspartic acid and assaying the degree of aspartic acid racemization within the tooth dentin has resulted in chronologic age assessment with error rates as low as ± 3 years.^{24,25}

Radioactive ¹⁴C

Although ¹⁴C dating has been an archeological tool since 1949, it has been developed as an age estimation tool relatively recently. When extensive, above-ground nuclear testing began in the mid-1950s, large amounts of radioactive ¹⁴C was released into the Earth's atmosphere until global treaties ceased above-ground testing in the mid-1960s. The ¹⁴C mixed homogeneously within the atmosphere and was incorporated into the tissues of plants and animals in amounts equal in concentration to that of the current atmospheric levels. Knowing the measured atmospheric levels of ¹⁴C during its release and understanding the decay rate of ¹⁴C, date of birth can be estimated from biologic tissues that are inert and biologically inactive.

Tooth enamel is rich in ¹⁴C and is metabolically inactive. Forensic radiocarbon enamel analysis has resulted in identifying the date of birth of humans to within an error rate of ± 1.6 years.²⁶ Age assessment using this technique is limited by the earliest above-ground nuclear testing in 1955. The last tooth to complete its crown formation is the

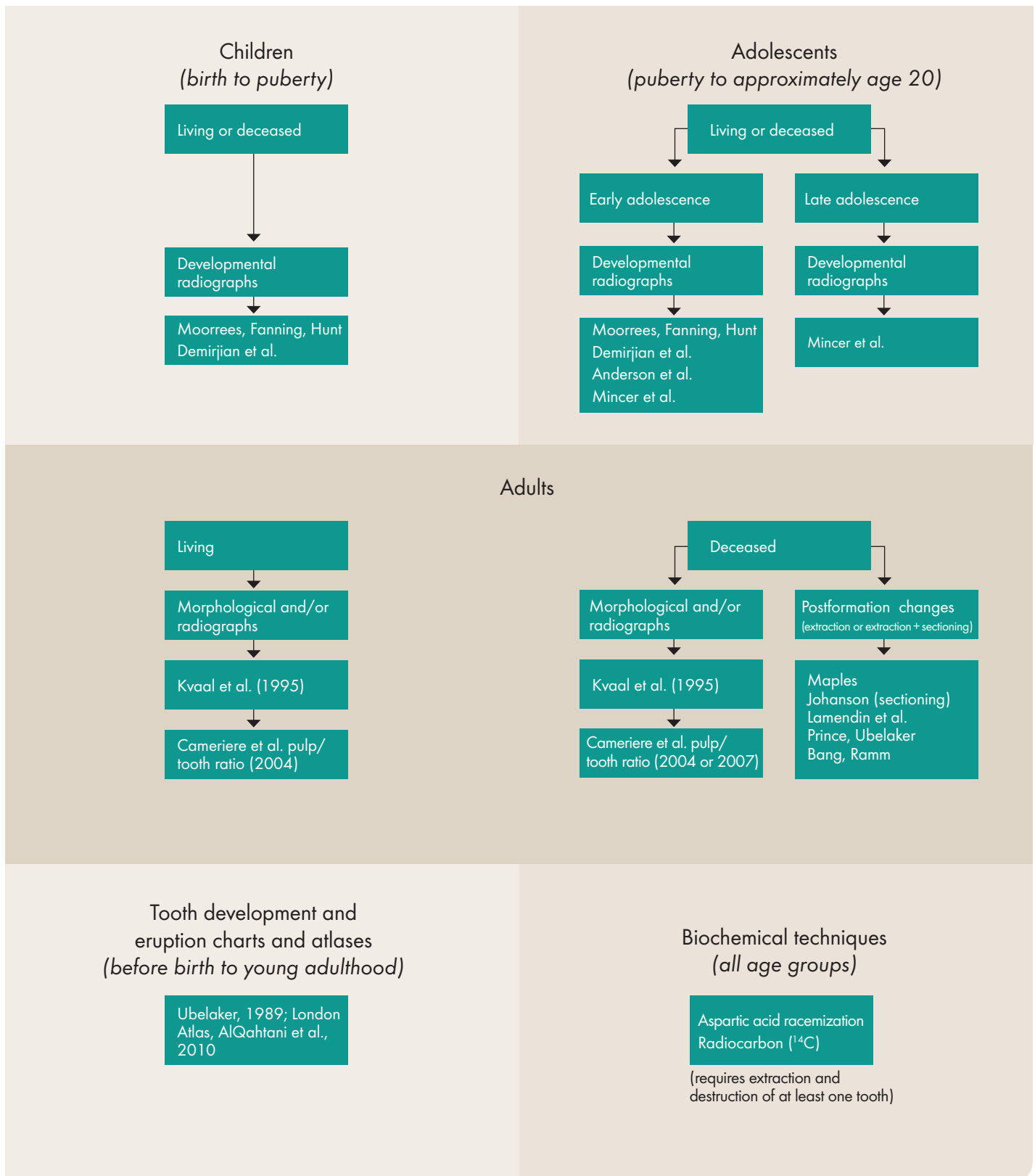


FIGURE 2. Dental age estimation procedures.

third molar at approximately age 12. Therefore, the earliest practical uses of this technique is on individuals born in or after 1943. However, a tooth enamel ^{14}C level at historic baseline atmospheric levels would indicate that the individual was born before 1943.

In 2013, Alkass et al. detailed research describing new possibilities for age assessment from teeth. When used in combination, techniques evaluating AAR, ^{14}C , ^{13}C and ^{18}O along with DNA analysis of the human dentition have produced a genetic and geographic profile of individuals. This profile includes information indicating sex, estimated year of birth, estimated year of death, information regarding the geographic region where the individual lived and a DNA profile.²⁷

Summary

Forensic age estimation involves the assessment of an individual's development, maturation and physical appearance in an effort to assess true chronologic age. This process is by no means an exact science, but it does rely upon sound scientific research. Accuracy depends upon the investigator applying the most suitable technique(s) based upon case circumstances. **FIGURE 2** is a flowchart that summarizes the selection process that many forensic odontologists utilize in evaluating individual case criteria for technique selection in age estimation cases. Moral, ethical, cultural and religious requirements may complicate, and thereby hinder, an investigator's ability to render accurate results. Accuracy is also dependent upon the use of the most current, valid, relevant and reliable population-specific data. When known, gender and ancestral background should be considered. Mitigating factors that may affect the forensic dental assessment of age include nutrition,

disease, medical treatment, habits and ancestral admixture. The scientific forensic community encourages the use of multiple techniques and repetitive measurements to obtain maximum reliability.²⁸ It is advisable, when accuracy is paramount, that the forensic odontologist consider the additional use of medical and anthropological techniques to corroborate his or her results. Furthermore, strict adherence to technique processes as described in the literature must be observed. ■

REFERENCES

- Müller N. Zur Altersbestimmung beim Menschen unter besonderer Berücksichtigung der Weisheitszähne. MD Thesis, University of Erlangen-Nürnberg 1990.
- Miles AEW. Dentition in the Estimation of Age. *J Dent Res* 42: 255-263, 1963.
- Lewis JM, Senn DR. Dental Age Estimation. In: *Manual of Forensic Odontology*, 5th ed. DR Senn, RA Weems, editors. Boca Raton, Fla.: Taylor & Francis Group. 2013.
- Ubelaker DH. Sex, stature and age. In: *Human Skeletal Remains: Excavation, Analysis, Interpretation*, 3rd ed. Washington D.C.: Taraxacum. 1999.
- AlQahtani SJ, Hector HP, Liversidge HM. Brief communication: The London atlas of human tooth development and eruption. *Am J Phys Anthropol* 142:481-490, 2010.
- Herschaft EE, et al. (eds.). *Manual of Forensic Odontology*, 4th ed. American Society of Forensic Odontology. 2006.
- Moorrees CFA, Fanning EA, Hunt EE Jr. Formation and resorption of three deciduous teeth in children. *Am J Phys Anthropol* 21:205-213, 1963a.
- Moorrees CFA, Fanning EA, Hunt EE Jr. Age variation of formation stages for ten permanent teeth. *J Dent Res* 42:1490-1502, 1963b.
- Demirjian AH, Goldstein H, Tanner JM. 1973. A new system of dental age assessment. *Hum Biol* 45:211-227, 1973.
- Demirjian A, Goldstein H. New systems for dental maturity based on seven and four teeth. *Ann Hum Biol* 3:411-421, 1976.
- Mincer HH, Harris EF, Berryman HE. The ABFO study of third molar development and its use as an estimator of chronological age. *J Forensic Sci* 38(2):379-390, 1993.
- Lewis JM, Senn DR. Dental age estimation utilizing third molar development: A review of principles, methods and population studies used in the United States. *Forensic Sci Int* 201:79-83, 2010.
- Lewis JM, Brumit PC. Dental age estimation and determination of the probability an individual has reached the legal age of majority. Paper presented at the annual American Academy of Forensic Sciences Meeting, February 21-25, Chicago, 2011.
- Maples WR. An improved technique using dental histology for estimation of adult age. *J Forensic Sci* 23(4):764-770, 1978.
- Wedel VL. Determination of Season at Death Using Dental Cementum Increment Analysis. *Journal of Forensic Sciences* 522:(6)1334-1337, 2007.
- Johanson G. Age determinations from human teeth: A critical evaluation with special consideration of changes after fourteen years of age. *Odontol Revy* 22:1-126, 1971.
- Bang G, Ramm E. Determination of age in humans from root dentin transparency. *Acta Odontol Scand* 56:238-244, 1970.
- Lamendin, et al. A simple technique for age estimation in adult corpses: the two criteria dental method. *J Forensic Sci* 37(5):1373-1379, 1992.
- Prince DA, Ubelaker DH. Application of Lamendin's adult ageing technique to a diverse skeletal sample. *J Forensic Sci* 47(1):107-116, 2002.
- Kvaal SI, Kollveit KM, Thomsen IO, Solheim T. Age estimation of adults from dental radiographs. *Forensic Sci Int* 74:175-185, 1995.
- Cameriere R, Ferrante L, Cingolani M. Variations in pulp/tooth area ratio as an indicator of age: A preliminary study. *J Forensic Sci* 49(2):317-319, 2004.
- Cameriere R, Ferrante L, Belcastro MG, Bonfiglioli B, Rastelli E, Cingolani M. Age estimation by pulp/tooth ratio in canines by mesial and vestibular peri-apical X-rays. *J Forensic Sci* 52(5):1151-1155, 2007.
- Ritz-Timme S, Collins MJ. Racemization of aspartic acid in human proteins. *Ageing Res Rev* 1:43-59, 2002.
- Ohtani S, Yamamoto T. Age estimation using the racemization of amino acid in human dentin. *J Forensic Sci* 36:792-800, 1991.
- Ohtani S, Yamamoto T. Age estimation by amino acid racemization in human teeth. *J Forensic Sci* 55(6):1630-1633, 2010.
- Spalding KL, Buchholz BA, Bergman LE, Druid H, Frisen J. Age written in teeth by nuclear tests. *Nature* 437: 333, 2005.
- Alkass K, et al. Analysis of radiocarbon, stable isotopes and DNA in teeth to facilitate identification of unknown decedents. *PLoS One* 8(7):1-12, 2013.
- Willems G. A review of the most commonly used dental age estimation techniques. *J Forensic Odontostomatol* 19:9-17, 2001.

THE CORRESPONDING AUTHOR, James M. Lewis, DMD, DABFO, can be reached at jmlewisdmd@knology.net.



Hope

There are certain things in life that don't reveal their true importance until they're gone. A smile is one of them. Restore it and you return a world of possibility. That optimistic smile and the hope it holds is why CDA unites and passionately supports your profession. Because the world is a better place when people are smiling, and that's thanks to you.

Join today.
cda.org/member





The Forensic Dentist: An Overview of Expert Roles in Animal Bite-Mark Investigations

Kenneth Cohn, DDS, MAGD, DABFO, and Ron Berman, BA, CFE, DABFE

ABSTRACT With increasing incidence of human/animal confrontation and the potential for injury or even death, dentists who choose to work in the forensic sciences may be called upon to utilize their skills and training to render opinions in criminal and civil cases. The authors will show how working in a cooperative environment and combining their skills with those of other experts can achieve the best result.

AUTHORS

Kenneth Cohn, DDS, MAGD, DABFO, is in private practice in The Villages, Fla. He is a courtesy associate professor at the College of Medicine Department of Pathology, Immunology and Laboratory Science and a consultant to the C.A. Pound Human Identification Lab at the University of Florida. Dr. Cohn serves as the chief forensic odontologist to multiple medical examiner districts in Florida, is past-president of International Veterinary Forensic Science Association and serves on state, federal and international disaster teams. *Conflict of Interest*
Disclosure: None reported.

Ron Berman, BA, CFE, DABFE, is a canine behavioral consultant and trainer who provides expert witness services and training for attorneys and insurance professionals regarding the forensic investigation and litigation of dog bites and pet-related injuries. Mr. Berman has participated in approximately 725 cases and forensic investigations and testified in civil, criminal and federal courts on 80 occasions. *Conflict of Interest*
Disclosure: None reported.

In the U.S., there are 237.4 million pets, notably, but not limited to, birds, cats, dogs, horses, reptiles and other small animals,¹ and there are more than 241 million adults age 18 years and older.² Doing the math, the potential number of human/animal interactions, both favorable and not, is considerable. Aside from the expected agricultural, companion and other legitimate interactions, there are many untoward consequences including provoked and unprovoked animal attacks, animal fighting schemes, exploitation, assault and abuse. One can hardly listen to the news or read a newspaper without a reference to a criminal or accidental negative encounter involving animals and humans. As far back as 1974, it was suggested that dog bites may be an unrecognized public health epidemic.³ Currently, because of the encroachment of population growth on natural habitats, many species are threatened (**FIGURE 1**).

Consider the following case examples. A man was attacked, killed and partially consumed by a mountain lion while mountain biking at Whiting Ranch Wilderness Park in southern Orange County, Calif., in 2004.⁴ On two occasions in Florida, a chance encounter between an alligator and a swimmer lead to death. In both swimmer cases, the investigating odontologist used bite-mark analysis to identify the alligators responsible for the attacks.⁵ Criminal complicity involving animals is more prevalent. In 2014, Alex Jackson was convicted of second-degree murder in California when his four pit bulls attacked and killed a woman who was out for a morning stroll. The dogs inflicted more than 200 puncture wounds. Jackson was sentenced to 15 years to life.⁶ In Okeechobee, Fla., a 4-year-old boy was viciously attacked by the family dogs outside his trailer while his mother was high on drugs inside. She claimed to have



FIGURE 1. Alligator in civilization

not heard the boy's screams yet a neighbor a half-mile away heard him.⁷ The mother committed suicide.

Concomitant with the rising occurrence of human/animal interactions is the increase in civil and criminal litigation, insurance claims, striking monetary settlements and public health concerns. All 50 states now have felony animal cruelty provisions including domestic violence protective orders, animal fighting as racketeering offenses and stiffer penalties for abuse offenders. There is a rising national consensus that egregious behavior involving animals should be punishable with severe monetary and criminal consequences.

The number of animal bites in the U.S. is impressive. There are 4.7 million dog bites, 400,000 cat bites, 45,000 snake bites, 250,000 human bites and tens of thousands of other small animal bites reported annually.⁸ Animal attacks on humans include those by dogs, bears, large cats, sharks, alligators, snakes and rodents. It is estimated that there are 20,000 rat bites alone in the U.S. annually⁹ (**FIGURE 2**). A

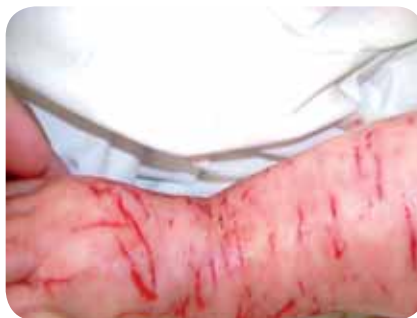

FIGURE 2. There are an estimated 20,000 rat bites in the U.S. annually.

fundamental understanding of bite marks, basic comparative anatomy, investigative procedures and the law is beneficial in both criminal and civil investigations. A proper treatise of this entire topic would be a sizable textbook in its own right. Hence, the intent of the authors is to provide an abbreviated understanding of bite-mark analysis and investigation with a selection of relevant examples. We will concentrate on canine cases because they account for the majority of the cases, injuries and costs.

Dog Bites and Related Costs

There are approximately 83.3 million owned dogs in the U.S., according to the 2013-2014 American Pet Products Association (APPA) survey.¹⁰ Although the social and psychological benefits of dog ownership are well-known, dogs are making new and increasing inroads into the fabric of our culture. An article in the *New York Post* reported that, according to data from the Centers for Disease Control and Prevention, more young U.S. women are choosing dog ownership over motherhood.¹¹ We are a society of pampered pets. APPA statistics show that spending on pets, dogs being a very large part, has consistently increased every year from \$17 billion in 1994 to more than \$53 billion in 2013.¹² Concomitantly, the perceived value of a pet has evolved from mere property ownership to the status of family member. People expect to be compensated for the loss of their animals. Factors to be considered are:

- The cost of treatment.

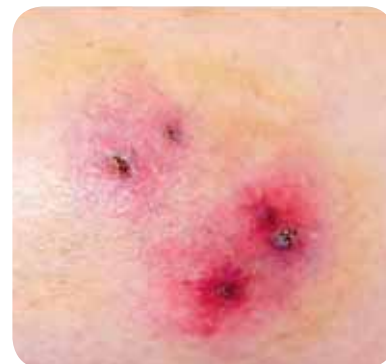

FIGURE 3. Small bite from a cat.

- Market or replacement value.
- Sentimental value including pain, suffering and emotional stress.
- Damages as punishment for wrongdoing.

The law in this area is still evolving, but the trend is toward special monetary value placed on pets.

Herman Bernitz, BChD, MSc, from the University of Pretoria, opined, "By owning a dog, man welcomes into his home a beast that preserves much of its primordial self, and is capable of inflicting a fatal bite wound."¹³ We love and fear our animal friends. The controversial debate over dangerous breeds typified by the pit bull breed is indicative of that dichotomy. Consider a recent court case involving a dog bite on a 4-year-old boy at a public playground by an unsecured dog that had bitten a 2-year-old girl on a previous occasion. The attorneys were amazed to find that half the prospective jury members hated the breed but the other half loved them. Pit bulls, once the breed closely associated with gangs and protection, are now family pets. Feared for their aggressiveness and strength, they are also loved and adored for those same qualities.

In 2012, dog bites and related injuries cost the insurance industry almost half a billion dollars and made up approximately one-third of all homeowners' liability claims. That figure, according to the Insurance Information Institute, is up about \$50 million since 2003. State Farm, one of the largest home insurers,

paid out \$109 million on nearly 3,800 dog-bite claims in 2013. California led in the number of dog-bite claims with 1,919, and claims paid, \$64.7 million.¹⁴ Rising costs are due to increasing costs of medical care in general and larger claims settlements. The majority of bites involve young children followed by the elderly, both high-risk groups. According to the American Society of Plastic Surgeons, there were about 26,935 reconstructive procedures to repair dog bites in 2013 at an average restorative cost of \$27,862.¹⁵

Most home insurance policies provide between \$100,000 and \$300,000 in liability. If the policy covers the insured's dog (modified by breed restrictions) and the victim sues and wins a settlement in excess of the policy limit, the dog owner or responsible party is personally liable. As a result, dog owners can find themselves losing their assets especially if punitive damages are assessed for egregious behavior. Punitive damages, when allowed by the judge and supported by a jury verdict, can add many hundreds of thousands of dollars to the settlement. In addition to civil consequences, all 50 states have felony animal cruelty provisions.

Types of Dog Bites and Dog-Related Cases

Dog-bite cases come in many sizes and shapes, from a superficial laceration or "nip" to a severely mauled victim exhibiting major tissue loss with punctures, contusions and lacerations over the entire body. In today's litigious society, culpability from damages caused by an animal encompasses a wide net of pockets. More than half of the states have statutes that make the owner or responsible party liable if their dogs cause injury.¹⁶ Scenarios range from a formally passive family dog to a criminal's highly aggressive Rottweiler and from a highly trained police dog to a pack of feral

dogs roaming the streets. Dog bites and related cases happen everywhere dogs and people commingle. The dog owner may not be the only one responsible for damages. California dog-bite statutes should be referred to for specific details about who is responsible and how damages apply to more than just a bite.

- The owner of any dog is liable for the damages suffered by any person who is bitten by the dog while in a public place or lawfully in a private place, including the property of the owner of the dog, regardless of the former

In 2012, dog bites and related injuries cost the insurance industry almost half a billion dollars and made up approximately one-third of all homeowners' liability claims.

viciousness of the dog or the owner's knowledge of such viciousness. California Civil Code section 3342.

- Any person owning, controlling or having care or custody of any animal shall be liable for any injury caused by such animal, and for any damage caused to any public property or to any private property. Beverly Hills Municipal Code:5-2-111.
- Special rules apply to children, such as provocation.¹⁷

There may be sizable financial gain/loss by either the plaintiff or defendant in a civil case tempting both parties to distort or simply delete relevant information regarding their case. Dog owners often fail to accurately remember previous incidents of aggression or simply choose to deny the dog's aggressive

history. Plaintiffs may embellish their account in order to increase the potential recovery in settlement or at trial. It is the responsibility of the experts to extract the truth, render an opinion based on their independent review of the evidence and hopefully educate the jury, enabling them to reach a just and fair verdict. In cases where a settlement between both parties is reached prior to trial, it is often the expert's testimony that helps both sides to more clearly see the real strengths and weaknesses of their case. When the experts offer conflicting opinions, it is the job of the jury to decide which expert is more credible.

Mammalian Dentitions

Carnivore teeth have adapted specifically to primary survival roles of hunting, catching and killing prey as well as specialized functions including grooming, social interaction, offensive and defensive behavior and feeding functions of crushing, shearing and grinding.¹⁸ The obvious example of this evolutionary adaptation are the canine teeth, which are the most prominent teeth and have the longest roots. As one might expect, the canines make deep, invasive wounds and are typically recorded in the bite mark. Although highly variable in size, the nonoccluding canine teeth are effectively adapted for incising, grasping, catching, holding and tearing. Cat and dog dentitions differ in that "unlike the dog who grasps the hide of an animal, then begins ripping by utilizing his own weight and strength, the feline employs a much different method. Cat canine teeth are better adapted for vertical punctures, not horizontal ripping. The canine teeth of felines are more structurally at risk so a cat will secure itself with its claws and puncture the neck at the base of the skull or suffocate the prey by restricting the windpipe" (FIGURE 3).

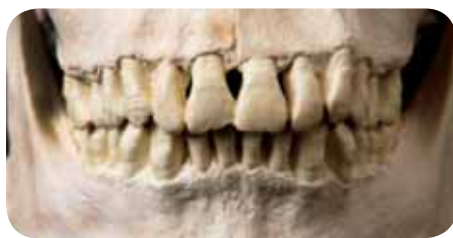

FIGURE 4A. Human.

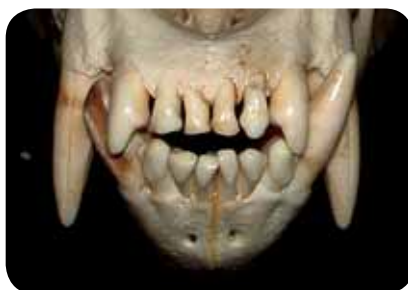

FIGURE 4B. Bear.

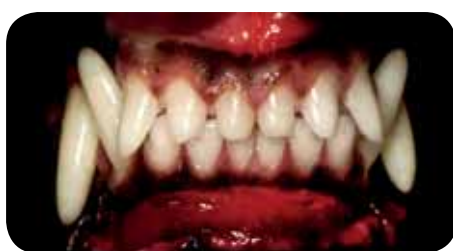

FIGURE 4C. Dog.

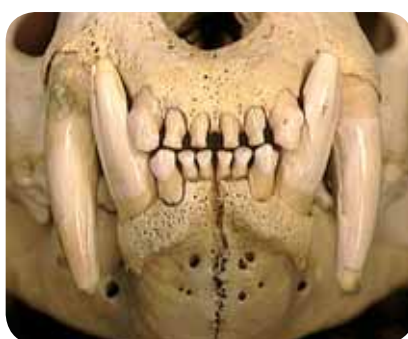

FIGURE 4D. Mountain lion.

FIGURES 4. Species dentition comparison.

Cats are highly specialized carnivores with less robust and more pointed posterior teeth for piercing soft tissue.¹⁹

Canine Dentition

Over the last 12,000 to 15,000 years of dog domestication, from the wolf subspecies *Canis Lupis* to today's varied domesticated dog species, functional changes in the dentition have occurred. For example, dietary needs determine premolar function and further differentiation in molar anatomy and size. Omnivores, such as humans, have teeth that are more conducive to crushing and do not possess carnassial teeth. Dogs have larger molars for crushing in contrast to human teeth. Many individual teeth fail to meet the opposing dentition or else they overlap and protrude between opposing adjacent teeth.

The dental formula for dogs is incisors, 3/3; canines, 1/1; premolars, 4/4 and molars, 2/3 for a total of 42 teeth. Breed variation shows considerable intercanine distance (ICD) variation ranging from 2.5 cm to 4.5 cm (mandible) and from 2.9 cm to 6.5 cm (maxilla) for North American

breeds.²⁰ The canine teeth become a good reference point in a bite-mark evaluation although the wound may be large and torn. Class differentiation between human and canine dentition is demonstrated by the number of incisors, with humans having four and dogs six per arch. This characteristic is beneficial in distinguishing between human bites and dog bites. Supernumerary teeth are common in dog dentitions so it is important to count the teeth for the evaluation.

Human and Animal Bite-Mark Comparison

The definition of a bite mark, according to *The Manual of the American Board of Forensic Odontology*,²¹ can be applied generally to both animal and human scenarios. A prototypical bite mark is described as a circular- or oval-patterned injury consisting of two opposing symmetrical U-shaped arches separated at their bases by an open space. Along the periphery of the arches is a series of individual contusions, abrasions and/or lacerations reflecting the size, shape, arrangement and distribution of the

class characteristics of the contacting surfaces of the human dentition. Dogs and humans, as mammals, share this general description (FIGURES 4A-D).

The starting point in a bite-mark evaluation is to establish if the patterned injury is, in fact, a bite mark. Class characteristics allow us to distinguish between species, animate and inanimate objects, adult versus child dentitions and upper versus lower arches. Examples of class characteristics are, as previously mentioned, the six incisors in the canine dentition versus four incisors in humans and as with all carnivores and many omnivores, predominate canine teeth.

Individualization or source attribution linking the suspect to the bite mark is determined by individual characteristics, which are defined as a variation of a feature, trait or pattern from the normal expected finding. Individual variation consists of both arch and teeth variation. Arch variation allows for distinguishing arch size and shape, which is evident in human versus animal dentitions. Teeth variation can consist of rotated and missing teeth, malposition, eruption variation, anterior-distal migration, broken teeth, damaged teeth, restorations, wear patterns and other variations.

The premise of bite-mark identification is based on the presumed uniqueness of the dentition and the accurate transferability of teeth marks to a substrate, particularly skin. Skin has viscoelastic properties that can result in distortion, making bite-mark identification potentially problematic. Inanimate objects such as Styrofoam, vegetables, hard candy and cheese are better recorders of teeth marks than the skin. Other factors resulting in potential inaccuracies include, among others, decomposition, positional variation, photographic error, time interval, bruising, healing, incomplete bite marks and the effects of age and medications.

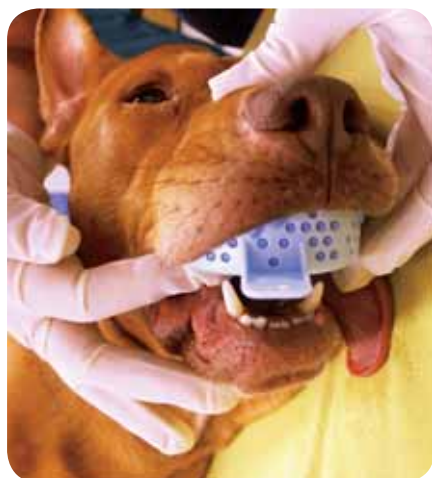

FIGURE 5. Vinylpolysiloxane impression.

The adult human ICD typically ranges from 2.5 cm to more than 4 cm compared to child ICD of < 3.5 cm. Deciduous teeth have a smaller mesial-distal width and may have spaces between the teeth. In theory, all the teeth in the arch could mark in a bite mark, but that does not happen. Rarely does the bite mark extend past the first premolars. Bite marks occur in a number of variations, including double, overlapped, single arch, marks through clothing, tearing and avulsion. Critical individual characteristics of the dentition are determined by teeth that are rotated, missing, malpositioned, dentally altered, worn, fractured, etc.

The size and shape of the dog skull is related to the variation in the size and position of the teeth, breed and weight. Note that medium-sized dogs can have a similar-sized ICD compared to humans. There are racial variations with human skulls and dentition but they are far more subtle compared to dog variations.

Bite-mark wounds can occur anywhere but often they are on the neck, head and groin. Particularly vulnerable are the arms used in a defensive posture. Claw marks can mimic teeth marks. However, these marks will be parallel, evenly spaced, superficial and without canine punctures. Bite-mark sequela often includes infection with rates ranging from 2-20 percent in dogs, 15-50 percent in cats and 9-50 percent in human bites.²² Exsanguination is the most common cause of death in severe dog bites.

Data Collection in Animal Bite-Mark Cases

Evidence collection, examination and interpretation of veterinary bite-mark cases offer unique challenges. As with any evidence collection, proper consent in the form of a court order or summons must be obtained, bearing in mind that the procedure varies with different jurisdictions and authorities.

There may be multiple animals and many bite marks making evidence collection and analysis more difficult. Another issue with larger animal bites is the destructive nature of the bites. Ripping, tearing and tissue avulsion can render the patterned injury uninterpretable. Eye-witness accounts of the incident may be beneficial to determine the dynamics of the attack particularly in determining the positions of the victim and animal during the incident. Collect evidence from the crime scene, the victim and the suspect animals if available. General principles to consider in investigation of dog-bite cases include:

- The scene. Photograph the scene. Determine the owner/caretaker and who was in charge of the animals at the time of the incident. Get eyewitness statements. Document all activities including all people present at the scene.
- The dog(s). Determine which animal(s) were involved. Secure DNA samples if appropriate and rabies tests if needed. Arrange to have the dogs sedated for photographs and dental impressions. Fabricate dental models of the dentition in either stone or casting acrylic. Import all the data into Photoshop for evaluation.
- The victim. Photograph the wounds. Get a statement of the incident. Collect DNA samples

if needed and take impressions if appropriate. Pour models and import information into Photoshop.

Animal DNA databases have been established so DNA from feathers, epithelial cells, hair, muscle and saliva can be collected procedurally similar to human protocols. By employing genetic-based techniques, proper identification of specific individuals, familial relationships and illegally obtained animals can be determined.²⁷

Animal skin is less vascular and bruising is less pronounced compared to humans. The veterinarian may need to expose the underlying soft tissue to uncover the patterned injuries. The powerful canine teeth may leave marks in bone through the soft tissue, which can be recorded with vinylpolysiloxane dental impression material (VPS). Because of the divergent canine teeth, the use of impression material is suggested rather than alginate to avoid tearing of the impression material. Likewise, the use of polyurethane plastic for the dental models is preferred for preventing the divergent canines from fracturing off the model versus stone or plaster models. If possible, two impressions and two models should be made for each arch (**FIGURE 5**). In addition to DNA, the stomach contents and feces should be checked for evidence.

Animal bite-mark/teeth comparisons can be done in the same manner as human bite-mark comparisons. Overlays are fabricated from the dental models for comparison. Direct comparison of the models onto the photograph of the bite mark or the actual bite mark can also be done. The protocol for patterned injury recording and comparison is outlined in the current American Society of Forensic Odontology (ASFO) *Manual of Forensic Odontology*²³ and the *American Board of Forensic Odontology Reference Manual*.

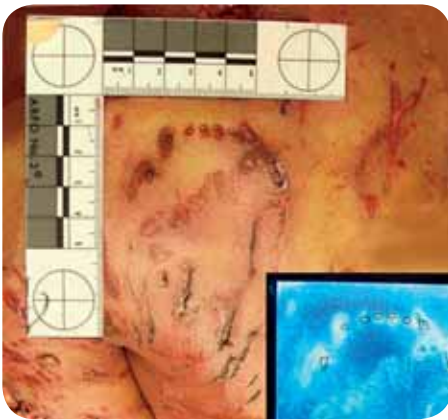


FIGURE 6. Multiple lacerations, contusions and avulsions caused by a pack of dogs.

Legal Anatomy of a Dog-Bite Case

Litigation in a dog-bite case typically starts with a summons to the dog owner telling him or her that he or she is being sued followed by a complaint that lists all of the reasons for the suit. At some point thereafter, discovery begins where the plaintiff and the defendant begin to gather facts that will support their case. Discovery usually consists of taking depositions from the plaintiff and defendant, witnesses, treating doctors and experts. When the facts of a case are strongly in dispute due to conflicting testimony from both sides and the potential dollar value of the case is high, various experts may be retained by either or both sides in order to help clarify important issues.

Canine Aggression

Canine aggression is typically either offensive or defensive. Most forms of canine aggression are fear-based responses such as territorial aggression, maternal aggression, protective aggression or food aggression in an attempt to deal with a real or perceived threat. Note that dog-on-human aggression and dog-on-dog aggression are two distinct behaviors and that a dog that displays one will not necessarily display the other.

A dog that bites one time, usually in

an inhibited manner, and then releases on its own is generally demonstrating defensive response to a stimulus the dog regards as a threat. This scenario is often found in cases where the victim has provoked the dog in some fashion. The dog is trying to increase the distance between itself and the source of the threat. In some situations, when a dog has already demonstrated fear aggression in the past, it may be that the dog's fear makes it overly reactive and a normal greeting from a friendly stranger may be perceived as a direct threat. Conversely, a dog that runs up and attacks a person on or near its perceived territory is acting offensively. The dynamics of an offensive attack are usually different from a defensive attack in that one typically finds multiple wounds often on different parts of the body. The wounds are more aggressive, deeper and there is more tissue damage. Other dynamics found in a serious offensive dog attack is shaking, where the dog bites, holds on and shakes its victim and generally will not end the attack on its own. Pack mentality can be particularly lethal. In 2003, an elderly woman was exiting her car at home when she was viciously attacked by a pack of six dogs belonging to a neighbor. The owner had been cited by animal services on multiple occasions for the unrestrained aggressive behavior of his dogs. The victim was brutally attacked and suffered multiple lacerations, contusions and avulsions over her entire body, which caused death by exsanguination. The owner of the dogs testified that he didn't know how long the attack had been going on but "they were chewing on her, all right."²⁴ The odontologist was able to match at least one of the many bite marks to each of the dogs involved in the mauling²⁹ (FIGURE 6). A plea deal was rejected and he was convicted. He lost the appeal and died while serving a 12-year sentence.²⁵

Typical Issues in Dog-Bite Cases

Whether a dog had demonstrated dangerous and/or vicious propensities prior to an incident will usually be an important factor in most dog-bite cases. Dog owners often, in an attempt to protect both their financial and personal interests, do not give accurate information about their dogs' past behavior. Owners can consciously or unconsciously deny their dogs' aggressive nature the same way a parent of a bully may choose to blame other kids or teachers for the child's bullying behavior. Just as often, plaintiffs can overly embellish the particulars of their incident.

The most common issues in a dog-bite case are:

- Is the victim's wound(s) from a dog bite or another source?
- Did the victim provoke the dog?
- Was more than one dog involved? Which dog did the biting?
- Did the incident happen the way the victim or the dog owner indicated? Experts are needed to establish the veracity of these statements.
- Did the dog have a history of aggressive behavior to humans and/or other animals?
- Were the owners (caretakers, landlords, etc.) aware of the dangerous propensities of the subject dog(s)?

More than half of U.S. states have a strict liability statute that makes the dog owner fully liable if his or her dog bites someone. Typically, the three defenses to strict liability are that the victim was trespassing at the time of the incident, the victim provoked the dog into biting him or the defendant did not own the dog at the time of the incident. It should be noted that someone who has been caring for the dog can also be sued if it can be shown that he or she has had the dog in his or her possession for a reasonable amount of time. An excellent resource

is the *Investigation, Management and Prevention of Animal Bites in California*, a manual published by the California Department of Public Health,²⁶ and web resources such as dogbitelaw.com.

The Experts

In issues regarding animal behavior, animal aggression, human/animal interaction and wound analysis, an animal expert with the right qualifications and experience in forensic investigation and testimony can be very helpful in clarifying specific issues. With regard to the actual etiology of the victim's wounds, especially when the wounds are likely from a source other than a dog bite, a forensic odontologist is best suited to evaluate the patterned injury. In cases regarding only dog bites, a forensic odontologist or an experienced court-qualified dog expert can offer expert opinions in court. In certain cases, the ideal scenario is for the forensic odontologist and the dog expert to work in conjunction to present the best evidence to the jury.

The Dog Expert

A qualified dog expert will have the knowledge, background and forensic experience to perform a complete analysis of the information available as well as follow the information trail to discover new pieces of evidence that may clarify issues in the case. An important task for the dog expert is to do a forensic evaluation of the dog as well as an inspection of the scene. It is always important to evaluate the temperament and behavior of each dog involved. Another part of the evaluation is testing the owner's control over his or her dog by having him or her give basic obedience commands both on leash and off leash in a safe place. Although there will be varying accounts of the incident or prior incidents, the dog may likely be the only

witness that is completely neutral. Dogs simply do what dogs do under similar circumstances, as they are creatures of habit and have no ability to change their behavior because they are being evaluated.

It is imperative that the evaluator not attempt to recreate the incident but only create similar circumstances. It is also important that the evaluator not do anything that could be construed as invasive or provocative, especially if the plaintiff claims that he or she did not provoke the dog. Ultimately, the purpose of the evaluation is to give a

It is imperative that the evaluator not attempt to recreate the incident but only create similar circumstances.

visual and experiential evaluation of the dog to the jury to help them make necessary decisions about the case. A poorly conceived or conducted evaluation may create more questions than answers and the opposing attorney will spare no effort in pointing that out in court.

In the end, the strongest pieces of evidence in a dog-bite case are the dog and the bite wounds. The wounds are direct physical evidence of how many times the dog bit the victim, whether the bites were inhibited (controlled aggression), the intensity of the aggression, whether the incident was defensive (offensive aggression), the possibility that the dog was provoked and damages resulted to the victim.

Videotaping is recommended so the evidence can be used at trial or

deposition. The dog expert will evaluate documents such as the dog's veterinary records, the animal control records, the emergency medical records, photos of the victim's wounds, etc. When necessary, the dog expert will inspect the scene of the incident and interview potential witnesses, including the owner, neighbors, veterinarian, forensic odontologist, trainers, pet sitters, groomers, kennel operators, etc. Based on the dog expert's background and experience, he or she may be qualified to testify on canine bite wounds. Even when qualified as an expert witness, the dog expert will often consult with a forensic odontologist in order to discuss and either confirm his or her analysis or entertain other theories related to the issues at hand. Although the dog expert may be qualified to testify about dog-bite wounds, he or she is not qualified to testify about what else may have caused the victim's wounds.

The Forensic Odontologist

The same forensic principles for human odontological investigation apply similarly to animal cases. Animal cases certainly can be more problematic because of the aggressive behavior of animal attacks that can result in substantial soft tissue mutilation and the difficulty in evidence interpretation. Because the animal cannot contribute verbally to the circumstances of the altercation, we must rely on the individuals involved or eyewitness accounts, which are notoriously inaccurate and biased. A team approach involving animal experts, law enforcement, veterinarian, pathologists, DNA specialists, crime scene technicians and other forensic partners can be assembled to investigate.

Social media is both pervasive and invasive — like it or not. One needs to be cognizant of social media “trying” cases in a public forum where activism

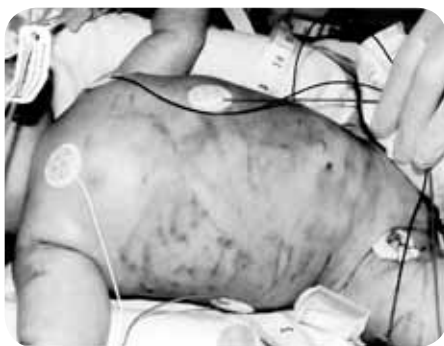

FIGURE 7. Evidence in a criminal case.

can have immense impact. Case in point, in 2013 an activist group in New York defended the case of Phineas, a golden Labrador residing in a small town in Missouri, that was accused of biting a girl while she played with friends. The events started out as a casual play day but morphed into an incident that polarized the entire town and gained national and international notoriety. More than 200,000 “experts” on Facebook opined as to the validity of the expert opinions and the proposed fate of Phineas. In addition, there was considerable hearsay, inappropriate accusations, misinformation and even threatened civil disobedience directing the investigation. A dog specialist and forensic odontologist were sought out as experts by the corporate advocate. The social media campaign and litigation went on for more than a year. Ultimately, Phineas was exonerated and taken off doggie death row. He was moved to a secure location only to go missing to an undisclosed new home.²⁷ The influence of e-opinions on outcomes cannot, and should not, be ignored.

The forensic odontologist should be aware of deliberate attempts to obscure criminal activity by involving an animal. A rush to judgment, bias in its many iterations, lack of critical evidence, failure to follow up on leads and many other considerations can lead to false conclusions. Another case in point involved a law enforcement officer, a dog and a charge of child neglect and abuse that occurred in Central Florida a few years ago. The two-month-old female

was found with multiple contusions, superficial lacerations, multiple posterior rib fractures, internal bleeding and a lacerated spleen while under the care of her father. The child protection team and state’s attorney felt there was sufficient cause to charge the father.

The patterned injuries on the child were determined by the odontologist to be superficial dog bite marks that neither the prosecution nor the defense disputed (**FIGURE 7**). The issue was whether the dog was responsible for the extensive internal injuries or if the father caused the crushing injuries while attempting to conceal his culpability by causing the dog to make the marks. The injuries on the skin were superficial and the contention by the state’s attorney was that the dog did not “bite” with sufficient force to cause the extensive internal injuries. There was no history of aggression from the dog and no indication that the dog was culpable in the life-threatening injuries sustained by the infant. In fact, the dog was sleeping next to the calm child. A two-year investigation ensued culminating with a two-week trial including testimony from several medical examiners, a dog behaviorist, a forensic odontologist, law enforcement officers, radiologists, pediatric specialists and other medical personnel. Ultimately, the verdict returned was that the defendant was not guilty of all charges.²⁸

Another more egregious case occurred in Ontario, Canada, where a 7-year-old girl was found dead in her basement. The initial pathologist reported more than 80 stab wounds from a knife or scissors. The mother was charged with second-degree murder, placed in isolation and her other children removed from her custody. Coincidentally, the neighbor’s pit bull dog was in the basement at the time of the incident and had a “reddish” substance on the fur and collar. The victim’s blood

was found to be in the shaved fur and there was hair in the feces. The original odontologist concluded that “the marks (were) completely inconsistent with dog bite marks, either domestic or wild ... without equivocation the markings seen on the deceased are not dog bite marks.” The prosecution’s pathologist testified “as absurd as it is to think that a polar bear attacked the victim, it is equally absurd that it’s dog wounds.” Ultimately, other forensic specialists were appointed to investigate and testified contrary to the original findings. After a long legal battle the charges against the pit bull owner were dropped and there was a multimillion-dollar settlement for malicious prosecution, false imprisonment and gross negligence.²⁹

Stakeholders in crime cases that may involve animals may be compromising the investigation by assuming the evidence must be either animal or human related. It may well be both. Investigators should be prepared to distinguish between human and animal injuries and utilize cross-trained analysts.

Members of the odontology team may be called to assist in animal-on-animal or human-on-animal abuse cases. Domestic violence and animal criminal cases, some involving biting, may involve human abuse, animal fighting, gang violence, sexual abuse, hoarding, torture and a host of other sociopathic behaviors. A bite-mark case may expose serious underlying family or individual dysfunction and psychopathy and follow-up is paramount. The American Human Society³⁰ reported disturbing animal and domestic abuse violence facts: Sixty-eight percent of battered women report that there had been violence toward their animals, 13 percent of intentional animal abuse cases involve domestic violence and 70 percent of animal abusers have records for other crimes. There is a long list of animal



FIGURE 8. Bane, one of the Presa Canario dogs that attacked Diane Whipple.

abusers who became infamous killers. Serial killer Keith Jesperson boasted, “No longer did I search for animals to mistreat. I now looked for people to kill. And I did. I killed over and over until I was caught.”³¹ Biting and animal abuse is a juvenile behavioral predictor of future, more serious and deadly behaviors.

Criminal Case History: San Francisco Dog Mauling

Arguably the most sensationalized dog attack in the U.S. is the 2001 Diane Whipple case. It had so many unique, horrifying, fascinating and bizarre components that it can serve as the quintessential example of the complexities of an animal attack culminating in criminal and civil penalties.

This case not only was a major catalyst for what was to become “breed discrimination” by insurance carriers against breeds associated with higher bite rates,³² it also spawned multiple lawsuits:

- A criminal case against the married defendants, Robert Noel and Marjorie Knoller, for involuntary manslaughter and fostering a mischievous animal that killed a human being.
- A separate charge of second-degree murder against Knoller who was present and claimed to have control over the dogs during the incident.
- Two civil cases were filed, one by Sharon Smith, Whipple’s partner, and the second by Whipple’s mother, against the owner of her apartment.

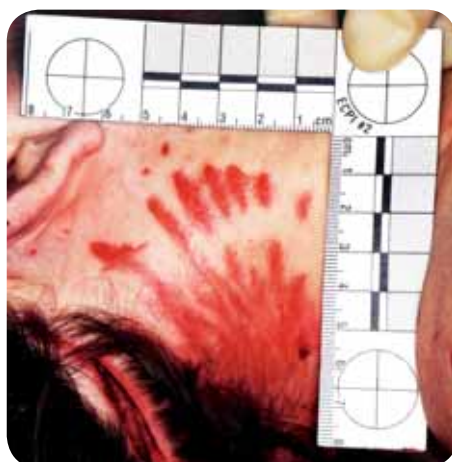

FIGURE 9. Fatal bite marks caused by the Presa Canario dogs on Diane Whipple’s neck.

What makes this case so incredible are the bizarre ancillary issues that came to light during the criminal trial that no doubt affected both the tone of the trial, public perception, media coverage and the jury’s final verdict. First, Diane Whipple, a lesbian, was an attractive 33-year-old lacrosse coach at St. Mary’s College. At the time of the incident, it was not legal for a gay partner to sue for wrongful death.³³ Sharon Smith, Whipple’s partner, became the first gay person in the U.S. to file a wrongful death civil suit on behalf of a partner.⁹ The defendants were criminal defense attorneys and the dogs were of a breed most people had never heard of prior to this incident. The dogs were owned by two convicts serving life sentences without parole in a California maximum-security prison. Both convicts were members of the white-supremacist Aryan Brotherhood terrorist group. To this day, some of the facts of what happened are still not clear but a general scenario of the events is available from numerous accounts. For a detailed journalistic account of this case, refer to the book *Red Zone — Behind the Scenes Story of the San Francisco Dog Mauling* by Aphrodite Jones.³⁴

On Jan. 26, 2001, Diane Whipple was viciously attacked by two Presa Canario dogs belonging to Knoller and Noel (**FIGURE 8**). While what actually happened within the estimated 12-minute attack was in dispute,

the horrific results were not.

The criminal trial was held in Los Angeles because of the incredible amount of publicity. Boyd Stephens, MD, the chief medical officer of San Francisco, testified that Whipple sustained massive injuries on 77 areas of her body (**FIGURE 9**). Whipple died of asphyxiation and exsanguination. Dr. Stephens also stated that Whipple was killed in the same way a lion pounces on its prey and sustained lacerations and cuts everywhere except for the soles of her feet and the top of her head. The most severe wounds were to her neck, where her jugular vein was severed and her larynx was punctured. The forensic odontologist identified several dog bites and indicated they matched the teeth of one of the two dogs that mauled Whipple.

Prosecutors maintained that the defendants knew their dogs were dangerous and did nothing to prevent Whipple’s death. The defense attorneys offered a different story. Based on the dog expert’s investigation there appeared to be a good bit of grandstanding going on because of massive press attention. Contrary to the prosecution’s stand that there were numerous examples of aggression prior to this incident, almost all of those turned out to be dog-on-dog aggression, which is not relatable to dog-on-human aggression and would not support knowledge by the owner of the dog’s aggression toward humans.

The jury found Noel and Knoller guilty of involuntary manslaughter and owning an animal causing the death of a human being. Knoller was also found guilty of second-degree murder. The State Bar of California suspended their licenses to practice law and Noel was disbarred several years later.

Another unusual aspect of this case is that Knoller filed a successful appeal and was awarded a new trial in May 2005.

However, the Court of Appeals reversed that decision and reinstated the second-degree murder conviction. Then on June 1, 2007, the California Supreme Court rejected the Court of Appeal's decision and remanded the case back to the trial court for reconsideration. Finally, on Sept. 22, 2008, the court reinstated the conviction for second-degree murder and sentenced Knoller again to 15 years to life. In 2010, the First District Court of Appeal unanimously upheld Knoller's conviction and she is currently serving her sentence at Valley State Prison for Women in Chowchilla, Calif.

Summary

With increasing incidence of human/animal confrontation and the potential for injury or even death, dentists who choose to work in the forensic sciences may be called upon to utilize their skills and training to render opinions in criminal and civil cases. Dentists acting as forensic odontologists work best in a cooperative environment combining their skills with those of other experts such as attorneys, law enforcement, medical examiners and qualified experts with specialized knowledge of the various animal species involved. In dog-bite cases specifically, although some of the issues to be addressed can be within the realm of both the forensic dentist and qualified dog expert, the unique skill sets of each can often serve to both enhance and support the findings of the other. ■

REFERENCES

1. American Pet Products Association (APPA). 2013-2014 National Pet Owners Survey Statistics: Pet Ownership & Annual Expenses. americanpetproducts.org/Uploads/MemServices/2013_14NPOSBackgroundandPurpose.pdf Accessed Sept. 9, 2014.
2. quickfacts.census.gov/qfd/states/00000.html. Accessed Oct. 9, 2014.
3. Harris D, Imperato PJ, Oken B. Dog Bites—An Unrecognized Epidemic. *Bull NY Acad Med* 50(9): 981-1000, Oct 1974.
4. Hanley C, Yoshomo K, Anton, M. Mauled Man May Have Been Fixing Bike. articles.latimes.com/2004/jan/10/local/me-lion10. Accessed Aug. 21, 2014.
5. Personal case file.
6. Dobuzinskis A. California Man Whose Pit Bull Killed Woman Gets 15 Years to Life. www.reuters.com/article/2014/10/03/us-usa-dog-murder-idUSKCN0HS1NN20141003 Accessed Oct. 15, 2014.
7. Personal case file.
8. www.healthychildren.org/English/health-issues/conditions/from-insects-animals/Pages/Animal-Bites.aspx. Accessed Oct. 15, 2014.
9. Abrahamian FM, Goldstein EJ. Microbiology of Animal Bite Wound Infection. *Clin Microbiol Rev*, 2011 Apr;24(2):231-246.
10. APPA releases 2013-14 National Pet Owners Survey. media.americanpetproducts.org/press.php?include=144262. Accessed March 10, 2014.
11. Antenucci A, Kli D. nypost.com/2014/04/10/more-young-women-choosing-dogs-over-motherhood. Accessed Oct. 12, 2014.
12. Randolph M. Compensating an Owner when a Dog Is Injured or Killed. www.nolo.com/legal-encyclopedia/free-books/dog-book/chapter9-6.html. Accessed Sept. 6, 2014.
13. Bernitz H, et al. The individualization of a dog bite mark: a case study highlighting the bite mark analysis, with emphasis on differences between dog and human bite marks. *Int J Legal Med* 2012 May;126(3):441-6. doi: 10.1007/s00414-011-0575-4. Epub 2011 May 3.
14. Dog Bite Liability. Insurance Information Institute, May 2014. www.iii.org/issue-update/dog-bite-liability. Accessed May 2013.
15. Reconstructive Plastic Surgery Statistics. www.plasticsurgery.org/Documents/news-resources/statistics/2013-statistics/reconstructive-procedures-national-trends-2013.pdf. Accessed May 2013.
16. Strict Liability: Dog-Bite Statutes. www.nolo.com/legal-encyclopedia/dog-bite-statutes.html. Accessed Oct. 25, 2014.
17. dogbitelaw.com/california/liability-based-on-the-dog-bite-statute-in-california.html. Accessed Oct. 23, 2014.
18. Hillson, S. *Teeth*. 2nd ed., p. 46. New York, Cambridge University Press. 2005.
19. Willis B. Scotching the Myth. scotcats.online.fr/abc/identification/bitemarks.html.
20. Tedeschi-Oliveira SV, et al. Inter canine Distance in the Analysis of Bite Marks: A Comparison of Human and Domestic Dog Dental Arches. *J Forensic Odontostomatol* 2011 Jul 1;29(1):30-36.
21. www.abfo.org/resources/abfo-manual. August 2013.
22. McGrath C. Bites: Human and Animal. www.carpa.org.au/Ref%20Manual%204th%20Ed/Emergency%20&%20assessment/Bites_human_animal.pdf. Accessed Oct. 29, 2014.
23. *Manual of Forensic Odontology*. 5th ed., CRC Press, Boca Raton, Fla. 2013.
24. Miller S. Pit Bulls Take Life. www.ocala.com/article/20031213/news/212130308. Accessed Nov. 2014.
25. Personal case file.
26. California Department of Public Health, Veterinary Public Health Section. *Investigation, Management and Prevention of Animal Bites in California*. 3rd ed., April 2014.
27. Personal case file.
28. Personal case file
29. Dorian R. *Bite Mark Evidence: A Color Atlas and Text*. 2nd ed., pp. 222-240. 2011, CRC Press, Boca Raton, Fla.
30. Human Society of the U.S. 2011. Animal Cruelty Facts and Statistics – Statistics on the Victims and Current Legislation Trends. www.humanesociety.org/issues/abuse_neglect/facts/animal_cruelty_facts_statistics.html. Accessed November 2012.
31. King V, Keith Hunter Jespersen. www.crimelibrary.com/serial_killers/predators/jespersen_5.html. Accessed October 2014.
32. Breed Disowned by Homeowners' Insurance Corp. www.animallaw.info/article/case-against-dog-breed-discrimination-homeowners-insurance-companies. University of Connecticut School of Law 2004.
33. Minter S. Expanding Wrongful Death Statutes and Other Death Benefits to same sex partners. http://www.americanbar.org/publications/human_rights_magazine_home/human_rights_vol30_2003/summer2003/hr_summer03_expanding.html.
34. Jones A. *Red Zone – The Behind-the-Scenes Story of the San Francisco Dog Mauling*. July 1, 2003.

THE CORRESPONDING AUTHOR, Kenneth Cohn, DDS, MAGD, DABFO, can be reached at heritagelcfc@gmail.com.



Specialists in the Sale and Appraisal of Dental Practices
Serving California Dentists since 1966
How much is your practice worth??
Selling or Buying, Call PPS today!

**Practices
Wanted**

NORTHERN CALIFORNIA
(415) 899-8580 – (800) 422-2818
Raymond and Edna Irving
Ray@PPSsellsDDS.com
www.PPSsellsDDS.com
California DRE License 1422122

SOUTHERN CALIFORNIA
(714) 832-0230 – (800) 695-2732
Thomas Fitterer and Dean George
PPSincnet@aol.com
www.PPSDental.com
California DRE License 324962

6085 PERIO PRACTICE – SAN FRANCISCO BAY AREA

2014 collected \$2 Million. 7 Doctor days per week. Seller can work back. Beautiful 8-op office.

6083 MODESTO 2014 collected approximately \$450,000. 2013 collections totaled \$640,000. When Management devotes attention, practice performs better. Digital 5 ops with digital Panorex. Nice blend between PPO & HMO.

6082 TURLOCK Nice foundation to build upon. Part-time office collected \$300,000+ in 2014. Everything new since 2008. 4-ops and digital. Convenient location.

6081 SANTA CLARA El Camino Real location. 2014 collected \$687,000 on 24-hour week. Available Profits of \$305,000. 2-days of Hygiene. 5-ops in 1,700 sq.ft. With attention, this can be a \$1+ Million/year performer.

6080 PLEASANTON - DUBLIN AREA 8+ days of Hygiene. \$450,000 invested in 6-op office. Consistent \$900,000+ per year performer. Attractive transition arrangements available.

6079 BERKELEY'S ALTA BATES MEDICAL VILLAGE – "SOLD" Strong performer on Owner's 24 hour week. 2014 collected \$676,500. Patient foundation anchored by 4-days of Hygiene. Endo and OS referred. Renowned Medical Village has regional draw.

6078 FRESNO Strip center practice on West Shaw Avenue. 2014's Collections totaled \$383,000 with Profits of \$192,000. Practice will do better with Successor who devotes full attention here. 4-ops. Full Price \$245,000.

6077 PERIO PRACTICE – SAN FRANCISCO'S NORTH BAY Highly regarded and located in desirable family area. On 3.5 day week, revenues were \$1 Million in 2014 with profits of \$400,000. Beautiful facility with 4-ops.

6075 MONTEREY BAY AREA Digital, paperless and well positioned for future. 2014 collected \$1.47 Million with Profits of \$690,000. 7+ days of Hygiene. First Quarter of 2015 collected \$449,000. Extremely unique opportunity.

6074 FREMONT – "SOLD" 2014 collected \$643,000. 4 day Hygiene schedule booked 6-months out. Beautiful office. Full Price \$325,000.

6071 CHICO Strength is 4-day Hygiene schedule. Retiring DDS focuses on restorative. Endo, OS, Perio & Pedo referred. 2014 collected \$450,000. Beautiful 4 op office. Full Price \$150,000.

6070 VISALIA Strong foundation and well-positioned for ambitious successor. Strong Hygiene Department, beautiful facility, well equipped. Digital throughout. Not a Delta Premiere practice.

6068 KINGSBURG Great family community south of Fresno. Owner works relaxed schedule doing restorative dentistry. Endo & OS referred. 2014 collected \$250,000+. Strong Profits. 3 Ops. Full Price \$135,000.

6067 MONTEREY - ADVANCED RESTORATIVE PRACTICE Strong foundation for DDS desiring quality restorative practice. \$310,000 invested here. Digital and paperless. 2014 collected \$400,000. "Out-of-network" practice. Considerable transition assistance available. Full Price \$185,000.

6065 SAN LEANDRO – "SOLD" 2014 collected \$438,000 on part-time schedule. Attractive 3 Op office with tranquil views of garden setting. Digital radiography includes Panorex.

ANAHEIM HILLS Perfect merger candidate for nearby DDS from North Orange County to Yorba Linda. Grossing \$400,000+. Seller will continue working with Buyer.

ARROWHEAD Great mountain practice. Hi identity location. Conservative part-time owner with Associate grosses \$400,000-\$600,000. Digital x-rays. Computers in ops.

BAKERSFIELD Emergency Situation. Widow needs help! Associate needed ASAP until practice is sold. Call 714-832-0230.

BAKERSFIELD AREA Small town. 4-op practice with building. Full Price \$350,000 includes real estate. Renovations make property look new.

BAKERSFIELD Lady DDS grosses \$800,000. Low overhead. Full Price \$550,000.

BAKERSFIELD Senior DDS retiring. \$650,000 gross. 5-ops in 3,000 sq.ft. building also For Sale. 37% overhead, high Net. Full price \$550,000.

CLAREMONT-UPLAND Gross \$500,000+. Refers \$250,000 in Ortho, OS, Endo. Hi identity. Seller can work back if acquired by Specialist.

COLTON Grossed \$30,000 last mth with Associate. 9-years left on great rent. Digital x-rays, intra oral camera. Owner nets \$3,000+/mth without working. Full Price \$250,000.

DENTAL LOCATIONS Bell and Bell Gardens

DIAMOND BAR Two Associates, part-time Owner collects \$1.2+ Million/year. Successor works harder and nets \$500,000. 2+ implant cases, 5+ OS cases referred monthly. \$6,000+/mth in cap checks.

HAWTHORNE Located in strip center at busy intersection. 6-ops, 2 equipped in 1,600 sq.ft. suite. Full Price \$95,000.

HUNTINGTON PARK Hi identity. 65,000 autos/day. 3 ops. Gold Mine! FP \$185,000.

INDIO Dental building across from City Hall. City offering special tax incentives. Great opportunity for DDS with vision.

INLAND EMPIRE Grossing \$10.6 Million. Some real property also included.

IRVINE Great location. 5-ops. Busy DDS wants Solo Group Partner.

IRVINE Solo Group Partner wanted. Buy 50%. Seller assures Buyer 45% net profit on production of \$450,000 first year. High end practice has Cerec and Cone Beam.

LA JOLLA HMO & PPO. 3-op office. 2-day week. Affluent community makes this almost cash practice. Roll-up sleeves and go to work. Full Price \$135,000!

LAKE FOREST 7 ops across street from major employer in Orange County.

LOS ANGELES HMO practice doing \$4+ Million. Includes real property.

MARINA DEL REY Gorgeous office. Grossing \$650,000.

MISSION HILLS Grossed \$350,000, nets 50%. Senior DDS wants to work-back 2.5 days. Seller will finance.

NORCO – CHINO HILLS Recently upgraded 8-Op office. Cone Beam, Cerec, digital radiography, high end equipment. Will do \$1.5 Million. Includes building.

REDLANDS Full price \$25,000. 25-year phone number and fictitious business name. Equip 3-ops for \$25,000. Great rehab opportunity which will grow with TLC.

REDLANDS Low overhead. Grosses \$20,000+/mth. Lease at \$1.00 sq.ft. FP \$250,000.

RIALTO Dental building on 2.3 acres. Land shall soon have \$8,000/mth in rent income.

SOUTH ORANGE COUNTY Grossing \$700,000. Ocean view. 4-ops. FPS\$700,000.

TEMECULA Long established HMO grossing near \$700,000. HMO checks \$4,000 to \$6,000 per month. Absentee owned.

TORRANCE Grosses \$350,000 with older DDS. 3-ops plumbed, 2 equipped.

TORRANCE/GARDENA Established 31-years. Chinese DDS retiring. Very profitable. Grosses \$200,000. Lots referred out.

TUSTIN Free standing dental building with 5 ops. Full Price \$1.4 Million.

TUSTIN Great location. 50% of building For Sale. Nearby DDS who flips their practice into this building can add another \$1 Million. Full Price for 2,000 sq.ft. is \$1.1 Million.

WEST LA Grosses \$1.2 Million. Seeks Korean Lady DDS for specialty team. Plan to grow to \$2 Million/year. Quality office. Full Price for 1/3 of goodwill \$350,000.

YUCCA VALLEY Hi identity location. Small office. Used to do \$500,000. Needs TLC. Full Price \$150,000 includes building.

****FOUNDERS OF PRACTICE SALES****
 120+ years of combined expertise and experience!

3,000+ Sales - - 10,000+ Appraisals

****CONFIDENTIAL****

PPS Representatives do not give our business name when returning your calls.



CALIFORNIA
PRACTICE SALES INC.



DENTAL TRANSITIONS™
VALUATIONS | SALES | CONSULTING

Specializing in selling and appraising dental practices for over 40 years!

LOS ANGELES COUNTY

CANOGA PARK (GP) – **Price Reduced!!** Seller is currently working 1 day/wk with ½ day of hygiene. 2 equipped operators. **Property ID #4357.**

CHATSWORTH (GP) – **Price Reduced!!** 5 equipped operators. Grossed \$918K in 2013. Projecting approx. \$948K for 2014. Buyer's net of \$398K. **Property ID #4537.**

LOS ANGELES – 65 years of goodwill Grossed approximately \$71K in 2013. Buyer's net of \$71K. Please contact your CPS Agent for more details. **Property ID #5008.**

LOS ANGELES - This practice with over 30 Years of goodwill, and approximately 60% of it's income comes from capitation. **Property ID #5012.**

LOS ANGELES (GP) - 3 equipped operators with digital x-rays in a 1,000 sq ft. office. The reception area was recently remodeled. Grossed approximately \$277,130 in 2014. **Property ID #5040.**

MISSION HILLS - Leasehold Improvements & Equipment Only! 8 equipped **Property ID #5014.**

MONTEREY PARK (GP) – Leasehold Improvements & Equipment Only! 3 equipped operators. **Property ID #4449.**

PASADENA (GP) - 3 equipped ops. Grossed approximately \$335K for 2014. **Property ID #5035.**

RESEDA – 3 equipped operators (stand up dentistry). Projecting approximately \$292,796 for 2014 with monthly revenues of \$24K. **Property ID #5017.**

ROSEMEAD – 2 equipped operators, lab/sterilization room, x-ray room, dark room and private office in a 790 sq ft suite. Projecting approximately \$119K for 2014. Low Sale Price! **Property ID #5019.**

SANTA CLARITA (GP) – This turn-key practice Reestablished the practice in September 2013. Great opportunity for a 1st time buyer. **Property ID #5013.**

SANTA MONICA - 3 equipped operators. Grossed \$265,485 in 2013 and projecting approximately \$265,796 for 2014. **Property ID #5022.**

TORRANCE – 3 equipped operators, Grossed \$321,051 in 2013. Practice is averaging \$28K in monthly revenue. **Property ID #4477.**

TORRANCE – 5 equipped ops. Grossed approximately \$493K for 2014. **Property ID #5036.**

ORANGE COUNTY

ANAHEIM – Leasehold Improvements & Equipment Only! 4 equipped operators in a 1,680 sq ft office. **Property ID #4535.**

ALISO VIEJO (Pedo) – 3 chairs in open bay, 1 plumbed not equipped op. Grossed approximately \$340K in 2014. Great practice. **Property ID #5031.**

FULLERTON (GP) – Established in 2002. Projecting \$554K for 2014. Buyer's net of \$189K. **Property ID #5010.**

FULLERTON – Leasehold Improvement and Equipment! On one the busiest intersections of Fullerton. 3 equipped operators. Some patient charts included. **Property ID #5028.**

GARDEN GROVE – 4 equipped ops and 1 plumbed (not equipped) op. Grossed approximately \$436K in 2014 **Property ID #5043.**

HUNTINGTON BEACH - Leasehold Improvement and Equipment Only! Modern Design. 3 equipped ops, 1 plumbed not equipped. Was built in June 2014. **Property ID #5032.**

IRVINE - Leasehold Improvement and Equipment! 10 equipped ops and 2 reception areas. **Property ID #5030.**

LAGUNA HILLS – 2 equipped ops. Approximately 20-25 new patients/mo. Ins/Cash/Cap (~\$500/mo). Grossed approximately \$319,024 in 2014. **Property ID #5033.**

ORANGE COUNTY PERIO – **Price Reduced!!** Grossed approximately \$972K in 2013 and projecting approximately \$1,016,000 for 2014 with a Buyer's net of \$260K. Please contact your CPS Agent for more details. **Property ID #5005.**

RANCHO SANTA MARGARITA – Leasehold Improvement Only!! 4 plumbed not equipped operators. **Property ID #4483.**

VENTURA, SANTA BARBARA & KINGS COUNTY

SAN LUIS OBISPO COUNTY – 6 equipped ops. Has monthly revenues of \$90K. **Property ID #5037.**

VENTURA (GP) - 4 fully equipped operators in a 1,862 (+ free bonus room) sq ft suite. Each operator has floor to ceiling windows for plenty of natural light. Grossed approximately \$423K in 2014. **Property ID #5039.**

SAN DIEGO COUNTY

VISTA - 35 years of goodwill. 4 fully computerized equipped operators. Grossed approximately \$883K in 2013. Has monthly revenues of \$73K. **Property ID #4507.**

EL CENTRO (GP) – This practice is located in a single story building. **Building is for sale.** 5 equipped operators. Grossed approximately \$304K for 2014. Buyer's net of \$132K. **Property ID #5023.**

SAN DIEGO COUNTY - Multi-Specialty practice. 7 equipped operators in an approximately 4,464 office. Grossed \$1,700,000 in 2013 and projecting approximately \$1,900,000 for 2014 with monthly revenues of \$165,000. **Property ID #4231.**

RIVERSIDE & SAN BERNARDINO COUNTY

APPLE VALLEY (GP) – 3 equipped ops. Has monthly revenues of \$42K. **Property ID #5044.**

APPLE VALLEY - 8 equipped operators. Seller is working 3 days/wk, Associate 1 day/wk and O.S. 1x/mo. Grossed \$707K in 2013 and Projecting \$722K for 2014. **Property ID #5009.**

HESPERIA (GP) – 4 equipped operators. Seller works 3 days/wk with 3 days of hygiene. Grossed \$260K in 2013 and projecting approximately \$336K for 2014. **Property ID #5007.**

INDIAN WELLS – Leasehold Improvements and Equipment Only!! Great opportunity for a TMJ, Sleep Apnea and GP. 4 equipped ops. **Property ID #5041.**

PALM DESERT – 5 equipped ops. Have monthly revenues of approximately \$28K/mo. **Property ID #4331.**

PALM SPRINGS – 3 equipped operators with Practice Web software and digital x-ray. Major equipment is approximately 2 years old. Suite is 1,200 sq ft. Seller is working 5 days/wk and sees approximately 8-10 patients/day. Income source is approximately 25% insurance, 65% cash and 10% Denti-cal. Does little advertising. Please contact your CPS Agent for more information. **Property ID #4487.**

RIVERSIDE – 6 ops. Projecting approximately \$550K for 2014. **Property ID #5006.**

Visit our Website and Social Media
pages for Practice Photos and Videos



youtube.com/mycpsteam



facebook.com/mycpsteam

CONTACT US FOR A FREE CONSULTATION

Phone: (714) 639-2775

WWW.CALPRACTICESALES.COM

CA DRE #00491323

Report Employee Injuries Immediately

TDIC Risk Management Staff

Workers' compensation covers a broad and multifaceted legal spectrum, but a few essential practices can help dentists manage an employee injury at work.

Key considerations include reporting the injury right away, authorizing medical care, avoiding judgment about the injury, maintaining open communication with the injured employee and treating the injured employee fairly.

Some policyholders mistakenly believe that not reporting employee injuries to the insurance company is a good business decision.

"Many times employers do not report claims on a timely basis," said Deborah Boyd, workers' compensation claims manager with The Dentists Insurance Company. "The law requires industrial injuries to be reported as soon as the employer has knowledge of an injury."

When reporting an employee injury, be prepared with as much information as immediately possible, including the name of the employee, date, time and location of the injury as well as a description of what happened.

While workers' compensation laws vary from state to state, statutes generally require employers to give a workers' compensation claim form to the employee within one working day after the work-related injury or illness is reported. State-specific workers' compensation information is available on the U.S. Department of Labor's website at dol.gov/owcp/dfec/regs/compliance/wc.htm. Request immediate return of the form from the employee and forward the claim form, along with a report of occupational injury or illness, to the insurance claims representative within one working day. Employers are required to authorize appropriate

"If an employee reports an injury, report the claim. You are required to make medical treatment available and provide a claim form to the employee."

medical treatment and make medical care available to injured employees.

TDIC advises dentists to report workers' compensation claims, even if they dispute the injury.

"TDIC only has 90 days to investigate and issue a denial, if appropriate, for a disputed claim," Boyd said, noting that it is not up to the dentist to discern if the injury is real or credible. "If an employee reports an injury, report the claim. You are required to make medical treatment available and provide a claim form to the employee."

You are not a policy number.

And at The Dentists Insurance Company, we won't treat you like one because we are not like other insurance companies. We were started by, and only protect, dentists. A singular focus that leads to an unparalleled knowledge of your profession and how to best protect you. It also means that TDIC is in your corner, because with us, you're never a policy number. You are a dentist.

Contact the Risk Management Advice Line at **800.733.0634**.

**Protecting dentists.
It's all we do.®**
thedentists.com



If you dispute that an injury occurred, report the claim and tell the claims representative you are disputing the injury.

"We will conduct the appropriate investigation," Boyd said. "If our investigation reveals that no benefits are due, we will deny the claim. While the employee will have recourse to overturn the denial, a late report may preclude us from being able to defend a claim denial."

Similarly, employers are advised that workers' compensation is "no fault" and that an injured employee is covered even if the employer thinks the injury was caused by employee behavior. Generally, workers' compensation in all states provides coverage for medical bills and lost wages for workers who are injured on the job, regardless of fault. In exchange, workers are not able to sue an employer for a work-related injury.

After filing a workers' compensation claim, the insurance company will begin to

administer benefits according to regulations. If an employee is off work due to the injury, TDIC recommends that dentists maintain communication during the period of disability. The employee should keep the dentist advised about the date that he or she expects to return to work.

TDIC recommends that dentists address "out-of-office" status in their office policy.

"In other words, have an office policy that is clear and tells the employee what is expected anytime they are out of the office on leave," Boyd said.

Fair and equal treatment of an injured employee is important to avoid allegations of retaliation or discrimination against the employee. Workers' compensation laws are state specific, but most jurisdictions have antidiscrimination laws protecting employees from retaliatory action when filing a workers' compensation claim.

For employers, the key to avoiding

liability is to treat an employee filing a workers' compensation claim or returning to work after an injury the same as other employees. Boyd said to be aware of reprimands or disciplinary action to an employee with an open workers' compensation claim. A record of dates, times and a brief description of incidents will keep information straight in the event of a claim.

A reasonable effort needs to be made to accommodate temporary work restrictions and provide transitional work (light duty) while the employee heals from the injury, and employers are encouraged to document these efforts.

Termination of an employee with an open workers' compensation claim is risky and may cause the employee to file a claim seeking additional compensation for discrimination. Dentists are strongly advised to consult an attorney before any consideration of dismissing an employee who has filed a workers' compensation claim.

"While workers' compensation is the exclusive remedy for workplace injuries, and your employee can't sue you in civil court for damages, your employee can sue you in civil court for wrongful termination or disability discrimination," Boyd said. "Civil employment lawsuits are costly to defend. In addition to payment for damages, claimants can recover their attorneys' fees in these types of actions. Therefore plaintiffs' attorneys are often motivated to take these cases to trial even if the actual damages aren't particularly large."

Also important is that the defense of a workers' compensation discrimination claim and any associated penalties imposed by a judge are not covered by workers' compensation insurance policies. Some workers' compensation insurance policies explicitly exclude workers' compensation discrimination claims, and there is no duty to defend them. ■

Consult with trained analysts about workers' compensation and other dental practice topics on TDIC's Risk Management Advice Line 800.733.0634.

PARAGON

DENTAL PRACTICE TRANSITIONS

The PARAGON Advantage

For more than 25 years PARAGON consultants have been dedicated to providing the best dental transition consulting services available in the country, guiding our clients through every step of the process.



Nationwide
Coverage



Dual
Representation



Local Market
Expertise



Your local PARAGON practice transition consultant is Trish Farrell

CALL: 866.898.1867 | FREE NEWSLETTER: PARAGON.US.COM

QUESTIONS MOST OFTEN ASKED BY SELLERS:

1. Can I get all cash for the sale of my practice?
2. If I decide to assist the Buyer with financing, how can I be guaranteed payment of the balance of the sales price?
3. Can I sell my practice and continue to work on a part time basis?
4. How can I most successfully transfer my patients to the new dentist?
5. What if I have some reservation about a prospective Buyer of my practice?
6. How can I be certain my Broker will demonstrate absolute discretion in handling the transaction in all aspects, including dealing with personnel and patients?
7. What are the tax and legal ramifications when a dental practice is sold?



QUESTIONS MOST OFTEN ASKED BY BUYERS:


1. Can I afford to buy a dental practice?
2. Can I afford not to buy a dental practice?
3. What are ALL of the benefits of owning a practice?
4. What kinds of assets will help me qualify for financing the purchase of a practice?
5. Is it possible to purchase a practice without a personal cash investment?
6. What kinds of things should a Buyer consider when evaluating a practice?
7. What are the tax consequences for the Buyer when purchasing a practice?



Lee Skarin & Associates have been successfully assisting Sellers and Buyers of Dental Practices for nearly 30 years in providing the answers to these and other questions that have been of concern to Dentists.

*Call at anytime for a no obligation response to any or all of your questions
Visit our website for current listings: www.LeeSkarinandAssociates.com*

**LEE SKARIN
& ASSOCIATES INC.**



Offices:
805.777.7707
818.991.6552
800.752.7461

CA DRE #00863149



Dr. Lee Maddox
LIC #01801165
(949) 675-5578
25 Years in Business



Dr. Thomas Wagner
LIC #01418359
(916) 812-3255
40 Years in Business



Dr. Dennis Hoover
LIC #0123804
(209) 605-9039
36 Years in Business



Dr. Russell Okihara
LIC #01886221
(619) 694-7077
33 Years in Business



Jim Engel
LIC #01898522
(925) 330-2207
42 Years in Business



Kerri McCullough
LIC #01382259
(949) 566-3056
35 Years in Business



Mario Molina
LIC #01423762
(949) 675-5578
35 Years in Business



Jaci Hardison
LIC #01927713
(949) 675-5578
26 Years in Business



Steve Caudill
LIC #00411157
(951) 314-5542
25 Years in Business



Thinh Tran
LIC #01863784
(949) 675-5578
11 Years in Business

PRACTICE SALES • PARTNERSHIPS • MERGERS • VALUATIONS/APPRISALS • ASSOCIATESHIPS • CONTINUING EDUCATION

NORTHERN CALIFORNIA

BAY AREA: Perio Practice. 2,120 sq. ft. w/6 Ops, Digital, Endoscopy, Piezosurgery, Dextrix. #CA167

CASTRO VALLEY: Practice & Building. Approx. 1,800 sq. ft., 3 Ops, 1 add'l Plumbed. 2014 GR \$373K, 4 day week. #CA251

FOLSOM: 2,420 sq. ft. w/50Ops, Shick Digital X-Rays, non-digital Pano, Carestream/Softdent software. #CA235

FOLSOM: FACILITY ONLY 1,200 sq. ft. w/3 Ops, digital X-rays & pano, new compressor #CA209

GREATER SACRAMENTO: General Practice. 1,500 sq. ft., 5 Ops (4 Equipped), Dexis Digital X-rays, Dextrix software. #CA239 **IN ESCROW!**

GREATER SACRAMENTO: General Practice. 7 Ops, 3,079 sq. ft. (Shared w/2nd DDS - Separate Practices), 2013 GR \$974K. #CA140

GREATER SACRAMENTO: General Practice. 2,100 sq. ft. w/6 Ops, Dextrix software, X-rays. Combined 2013 GR of \$1.1M. #CA237 **IN ESCROW!**

GREATER SAN JOAQUIN: Pedit Practice. Pano, Digital X-ray, 3 chairs. 2014 GR approx. \$700K. #CA230

GREATER SAN JOSE: Perio Practice. Fiscal-year GR \$1.3M. 5 Ops, 2 add'l Plumbed, in same loc. 28 years. #CA219 **IN ESCROW!**

MARIN COUNTY: Mill Valley. 1,260 sq. ft., 3 Ops, 1 add'l Plumbed. Dextrix, Digital X-ray, Intra-Oral. #CA224 **IN ESCROW!**

MENDOCINO COAST: General Practice. 4 Ops, 2,376 sq. ft. Dextrix, CAD/CAM. 2013 GR \$1M+. #CA181

N. COAST: Endo Practice. 6 Ops, 5 Plumbed, 3,300 sq. ft., Digital X-ray, Microscopes, EndoVision software. #CA214

N. EAST BAY: PRICE REDUCED! \$77K! General Practice + Bldg. 7 Ops. 2,324 sq. ft. 2012 GR \$885K. #CA108

NORTHERN CALIFORNIA: Perio Practice, Partnership Position. 6 Ops, 1,500 sq. ft. Dextrix. Owner Financing Available. #CA168

NORTHERN CALIFORNIA: Endo Practice. 3 Ops, 1 Plumbed, 1,200 sq. ft., 2 Microscopes, Digital. 2013 GR \$319K+ #CA158 **IN ESCROW!**

NORTHERN CALIFORNIA: Endo Practice. 4 Ops, 1 Add'l Available, 1,021 sq. ft., 2013 GR \$337K #CA169

OAKLAND: General Practice. Piedmont District. 3 Ops in shared office w/1,600 sq. ft., GR\$453K. #CA217 **IN ESCROW!**

PLEASANTON: Facility Only, Former Endo Ofc, Good GP Startup. 2 Ops, 1 Plumbed & Partially Eq. 975 sq. ft., #CA195

PLUMAS COUNTY: General Dentistry. Seller wants to retire ASAP, selling for \$95,000. 5 Ops, 4 Equipped. #CA240

SACRAMENTO: 7 Equip Ops in 2,400 sq. ft., 1 add'l Op Plumbed. Digital X-ray, Pano, Softdent software. 2014 GR \$626K+. #CA250

SACRAMENTO: PPO practice, 8 Ops in 3,700 sq. ft., Seller retiring. #CA238 **IN ESCROW!**

SACRAMENTO: Prosth. Practice. OWNER DECEASED. 4 Ops, 2,075 sq. ft. w/Digital Pano & Mac Practice software. 2014 GR \$960K+. #CA247

SAN FRANCISCO: General Dentistry. 3 Ops, 2 Equipped, 780 sq. ft., 2013 GR \$854K #CA191

SANTA CRUZ COUNTY: General Dentistry. 3 Ops, 1,100 sq. ft., Schick Digital. Dextrix. GR \$338K #CA550

SANTA ROSA: General Dentistry & Building. 3 Ops. 2013 GR \$542K w/Adj. Net \$182K #CA200

WALNUT CREEK: PRICE REDUCED! Prosth Practice. 3 Ops, Full Lab. 2013 GR \$399K w/adj. net. \$143K #CAM540 **IN ESCROW!**

CENTRAL CALIFORNIA

CENTRAL COAST: 6 Ops, 8 days of hygiene/wk. 2013 GR of \$2.3M and \$804K in adj. net. Dextrix, Digital, Paperless. #CA208

FRESNO: General Dentistry Partnership. 2013 Partnership GR \$4.7M. Selling Partner 2013 Net Inc. \$368K. #CA196

FRESNO: General Practice. 4 Ops, 1,739 sq. ft., CEREC, 61% Overhead. 2013 GR \$740K+. #CA20 **IN ESCROW!**

FRESNO: 5 Ops, 4 Equipped, 1,400 sq. ft., w/ Pano, Dextrix software, all digital. 3 years GR averaging \$409,000. Priced to sell. #CA243 **IN ESCROW!**

PORTERVILLE: General Dentistry. 6 Ops. 2014GR \$555K, 7 year old equipment, retail center. #CA223

TUOLUMNE COUNTY: General Practice & Bldg. 6 Ops, 2,000 sq. ft., 2013 GR \$1MM+ #CA197 **IN ESCROW!**

SOUTHERN CALIFORNIA

ANAHEIM: General Practice & Bldg. 6 Ops, 3 Equipped, 3 Plumbed. Near Disneyland. Est. 39 years. #CA186

ANAHEIM: 4 Ops, 5 add'l available, SoftDent, Digital X-rays and Digital Pano. 2013 GR 237K. #CA207 **IN ESCROW!**

BAKERSFIELD: General Practice. 4 Ops. Pano. Est. 20+ Years. 2013 GR \$521K. #CA193

BALDWIN PARK: General Practice. 5 Ops, 4 Equipped. 2013 GR \$286K w/Adj Net \$133K. #CA176

BANNING: General Practice. 6+ Ops. Paperless, Digital, EagleSoft. 8 Days Hyg/Week. 2013 GR \$1.5MM+. #CA183

BEVERLY HILLS: Small boutique practice. 2 Ops, 1 Equipped, Open Dental, Digital, 2014 GR \$120K on 3 days/wk.. #CA215

BEVERLY HILLS: 5 Ops, EagleSoft, Digital, CEREC. Long-term staff, newer equipment. 2013 GR 1.2M, adj. net. of \$406K. #CA210

GREATER LOS ANGELES: Perio Practice. 5 Ops. 34 Years of Goodwill. Call for More Information. #CA173

HUNTINGTON BEACH: General Practice., 3 Ops. Dextrix, Digital, Laser, Intra-Oral. Est.23 Years. #CA194 **IN ESCROW!**

IRVINE: NEW LISTING! General Practice, 5 Ops, 4 Equipped. PPO/FFS, GR of \$314K on a 3-day work week. #CA241

LOS ANGELES: General Practice. 9 Ops, 6 Equipped. Dextrix, Digital. Est.16 Years. 2013 GR 824K w/adj. net. \$355K #CA197 **IN ESCROW!**

LOS ANGELES: General Practice. 4 Ops, 3 Equipped, Est. 60+ years in prof. bldg.. 2013 GR of \$824K with \$355K adj. net. #CA211

N. ORANGE COUNTY: NEW LISTING! General Practice. 40Ops, Beautiful design, great location near freeway & shopping #CA234

PALM DESERT: NEW LISTING! Perio/ Implant Practice. 6 Ops, 5 Equipped, Dextrix, Digital, Pano, 20+ years of goodwill. 2014 GR \$805K with \$339K adj. net. #CA245

PALM DESERT: NEW LISTING! General Practice, 5 Ops, Est. for 32 years, 6 days of hygiene/week/ GR of \$824K and \$339K adj. net. #CA245

SANTA ANA: 6 Ops, Dextrix, Dexis, Pano, Laser. GR just over \$1M in 2013, higher in 2014. #CA221 **IN ESCROW!**

S. ORANGE COUNTY: General Practice. 5 Ops. EagleSoft, Schick, Intra-Oral. 2013 GR \$400K w/adj. net. \$136K #CA192 **IN ESCROW!**

S. ORANGE COUNTY: NEW LISTING! Pedit Practice with 4 Ops, 1 year new equipment, digital, Pano/ \$236K GR with room to grow. #CA222

SOUTH BAY, LOS ANGELES: NEW LISTING! General Dentistry. 3 Ops, Dextrix, Dexis, Pano, mostly FFS, 8 days hyg/week. \$1.1M GR in 2013. #CA218

SOUTH PASADENA: NEW LISTING! General Dentistry. 4 Ops, 3 Equipped, paperless, digital, est. 37 years. 2014 GR \$856K with \$271K adj. net. #CA244

TEMECULA: General Practice. 6 Ops. EagleSoft, 14 Workstations, Digital, CEREC, Pano. Est.26 Years, Long-Term Staff. #CA174 **IN ESCROW!**

TORRANCE: General Dentistry. 3 Ops, 2 Equipped. Est 19+ years. 2013 GR of \$333K with \$176K adj. net. #CA213

UPLAND: NEW LISTING! General Practice. 4 Ops, 3 Equipped. 25+ years of Goodwill. 2014 GR of \$221K with room to grow. #CA254

VICTORVILLE: General Practice. 3 Ops, 3 Plumbed, 2,150 sq. ft., Est. 34 Years, SoftDent. 2013 GR \$313K w/adj. net. \$147K #CA149

WEST COVINA: NEW LISTING! General Practice with 4 Ops in a retail center location. Dextrix, Digital, 35 years of goodwill. 2014GR of \$402K #CA233

WEST LOS ANGELES: NEW LISTING! General Practice, 4 Ops, newly built-out suite, desirable high rise. 50+ years goodwill. FFS. 2014 GR \$651K. #CA226

WEST HOLLYWOOD: General Practice, 4 Ops, Mediant, Intra-Oral Camera, Digital, Laser, 5 yr old equip. 2014 GR of \$613K . #CA212 **IN ESCROW!**

SAN DIEGO

CENTRAL SAN DIEGO: NEW LISTING! Very busy 6 Op General Practice with room to expand to 9 Ops. PPO, Dextrix, Digital. 2014 GR 1.7M. #CA231

DOWNTOWN: NEW LISTING! Leasehold sale. Modern and chic downtown office in prime location. 3 ops + room to expand. #CA232

LA MESA: NEW LISTING! General Practice. 4 Ops. 3 Equipped, FFS/PPO, Dextrix, Digital. 2013 GR \$342K , similar in 2014. #CA227 **IN ESCROW!**

LA MESA: General Practice. 3 Ops, 2,000 sq. ft. in a **REDUCED** Bldg. Dextrix, Laser, Digital. 2012 GR \$350K w/adj. net. \$155K. #CA127

N. COUNTY COASTAL: NEW LISTING! General Practice, 3 Ops, digital, Dextrix, FFS/PPO. 2014 GR of \$530K with \$228K adj. net. #CA253

N. COUNTY INLAND: NEW LISTING! General Practice & bldg. 4 Ops, PPO/FFS, Digital, Pano, Cerec. GR over \$1M. #CA216

SAN DIEGO: General Practice. 3 Ops. FFS, PracticeWorks. Located in Central San Diego. 2014 GR \$187K. #CA161

SANTEE: NEW LISTING! General FFS/ PPO Practice, 6 Ops, retail center, Dextrix, Digital, \$780K GR in 2014. 7 days of hyg/ week, long-term staff. #CA228

S. BAY AREA, SAN DIEGO: General Dentistry. 3 Ops, 4 days hyg/wk. Retail center, Dextrix, Digital Pano, PPO & FFS. Proj. GR 2014 \$562K. #CA206

OUT OF CALIFORNIA

HAWAII (MAUI): PRICE REDUCED! General Practice. 4 Ops, Approx. 1,200 sq. ft., GR \$636K #20101

NORTHERN CALIFORNIA OFFICE
1.800.519.3458

NEW www.henryscheinppt.com

SOUTHERN CALIFORNIA OFFICE
1.888.685.8100

Uses and Disclosures of Patient Health Information:

Part II

CDA Practice Support

The rules under which a dental practice may use or disclose patient health information (PHI) for public benefit and interest activities is the subject of this article. Last month's article reviewed HIPAA and state rules for required and incidental disclosures, as well as permissible uses and disclosures for treatment, payment and business operations. In all but required circumstances, a dental practice should use or disclose the minimum necessary information to accomplish the purpose of the use or disclosure of information.

HIPAA and state law permit the use or disclosure of PHI without a patient's authorization to third parties that benefit the public or perform in the public's interest, but only in specific circumstances. Other circumstances involving the same third parties may require a patient's authorization to use PHI. Below are the third parties and the circumstances under which patient authorization is or is not required to use or disclosure PHI.

Subpoenas, court orders and administrative orders. A dental practice must disclose PHI pursuant to a legally executed subpoena issued by a state or federal court, board, commission or administrative agency. Subpoenas and search warrants presented by law enforcement do not require patient authorization for the production of PHI. If presented with a civil suit subpoena, a dental practice may disclose information if the subpoena is issued by a California or federal court and is accompanied with either the patient's authorization or documentation that the patient has been informed of the subpoena. A dental practice should contact legal counsel if questions arise about a subpoena. An administrative order issued by a state or federal board, commission or agency is typically accompanied by a patient's authorization for release of information.

Law enforcement without a subpoena. Sometimes law enforcement will request a patient's information from a dental practice. Although it is prudent to insist upon a subpoena, HIPAA permits a dentist, without patient authorization, to release protected health information to law enforcement under the following circumstances:

- To report injuries resulting from criminal acts or deadly weapons.
- To respond to court orders, search warrants, court-issued subpoenas or regulatory agency order.
- To respond to requests for information to identify or locate suspects, fugitives, witnesses or missing persons.

- To respond to requests for information about a crime victim.
- To alert law enforcement of a suspicious death.
- To provide evidence of criminal conduct.

Before providing the requested information, verify the identity and credentials of the individual receiving it.

Mandated reporting. The obligation of a licensed dental professional to disclose possible domestic abuse, violence, neglect, criminal activity and other legal violations involving patients to appropriate agencies is not hindered in any way by HIPAA or California law. Patient authorization is not necessary.

When Looking To Invest In Professional Dental Space Dental Professionals Choose



For your next move,
contact: **LINDA BROWN**

Direct: (818) 466-0221
Office: (818) 593-3800
Email: LindaB@TOLD.COM
Web: www.TOLD.com
Cal BRE: 01465757

Linda Brown

**30 Years of Experience Serving
the Dental Community Proven
Record of Performance**

- Dental Office Leasing and Sales
- Investment Properties
- Owner/User Properties
- Locations Throughout Southern California

TOLD DRE 01132455
partners INC.
INDUSTRIAL/COMMERCIAL REAL ESTATE

Coroner. California law requires, and HIPAA permits, health care providers to release information upon a coroner's request to help identify the deceased, locate next of kin or investigate deaths that may involve public health concerns,

organ or tissue donation, child or elder abuse, suicide, poisoning, accident, sudden infant death, suspicious deaths, unknown deaths or criminal deaths. Authorization by the patient or a patient's representative is not required.

Social services agencies. If a minor patient is in the temporary custody of a social service agency or probation department or is a ward of the court, a dental practice may release to those entities PHI necessary for coordinating health care services and treatment for the patient.

Public health agencies. Incidences of communicable diseases, such as TB and measles, must be reported to a local public health agency. The report does not require patient authorization. Dental practices may provide, without patient authorization, patient information to local, state and federal health agencies for the purpose of preventing or controlling disease, public health investigations and public health surveillance. Dental practices also may report adverse events involving drugs or devices to the FDA MedWatch program.

Serious threat to health or safety. A dentist may disclose minimum necessary PHI when he or she believes such disclosure will prevent a serious or imminent threat to a person or persons. Such disclosures may be made without patient authorization to an entity that can prevent or lessen the threat.

Research. Before allowing PHI to be used without patient authorization for research, a dental practice is obligated to ensure the researcher has provided it with certain assurances required by HIPAA (see hhs.gov/ocr/privacy/hipaa/understanding/special/research). A dental practice also may use or disclose for research purposes and without patient authorization a limited data set of PHI. A limited data set does not include 16 specified identifiers.

Miscellaneous. PHI may be disclosed without patient authorization as authorized by workers' compensation laws and Cal/OSHA. ■

Regulatory Compliance appears monthly and features resources about laws and regulations that impact dental practices. Visit cda.org/practicesupport for more than 600 practice support resources, including practice management, employment practices, dental benefit plans and regulatory compliance.



PRACTICE SALES AND LEASING

**NOW IS THE BEST TIME IN YEARS
TO BUY OR SELL A PRACTICE!**



Paul Maimone
Broker/Owner

ARCADIA – (4) op comput G.P. Located in a well known Prof. Bldg. on a main thoroughfare. Cash/Ins/PPO pt base. Annual Gross Collect \$300K+ on a (3) day week. **NEW**

BAKERSFIELD #29 – (4) op comput G.P. (3) ops eqt'd, (1) add. plumbed. Located in a free stand bldg. Cash/Ins/PPO. Digital x-rays. Annual Gross Collect \$300K+ p.t. Seller moving. **NEW**

ENCINO – (3) op comput G.P. located in a prof bldg. on a main thoroughfare. Annual Gross Collect \$150K+ p.t. Cash/Ins/PPO. Below market Lease. Great Starter or Satellite. Seller retiring.

LANCASTER – (5) op comput. G.P. & Single Use Bldg. Be your own Landlord. (3) ops eqt'd (2) add plumbed. Located in a free stand bldg. on a main thoroughfare. Cash/Ins/PPO pts. Gross Collect \$300K+ on a (2) day wk. Digital. Total payment \$4K/mos w \$30K down. **WOW!**

LA VERNE – (7) op comput. G.P. (3) ops eqt'd (4) add plumbed. Located in a busy shop. ctr. w exposure/visibility & signage. Cash/Ins/PPO. Digital X-rays. 2014 Gross Collect ~ \$390K.

MONTEREY PARK – (6) op comput G.P. located in a street front suite on a main thoroughfare w exposure & visibility. Cash/Ins/PPO. Annual Gross Collect \$250K+ p.t. Seller retiring. **NEW**

PASADENA – Nearly New Turnkey Office w some charts. Newer eqt. Gorgeous!

RANCHO CUCAMONGA – (4) op comput. G.P. in a strip ctr. w visibility. (3) ops eqt'd (4th) op plumbed. Annual Gross Collect \$185K+ on 2.5 days/wk. Cash/Ins/PPO pts. Seller moving.

SHERMAN OAKS – (3) op comput G.P. in a well known, easily accessible Med/Dental bldg. Cash/Ins/PPO. Annual Gross Collect \$180K+ p.t. Great Starter or Satellite. Seller retiring.

So. KERN COUNTY – (6) op comput. G.P. located in a Bakersfield suburb in a small strip ctr. w exposure/visibility. Pano eqt'd. Limited competition. Cash/Ins/PPO pts. Annual Gross Collect. Approx. \$350K p.t. Seller is moving and is motivated. **NEW**

SANTA ANA – absentee owned (6) op fully eqt'd G.P. First floor street front location on a main thoroughfare. Exposure/visibility/signage. Cash/Ins/PPO. No HMO & No Denti-Cal. Pano eqt'd & Computerized. 2014 Gross Collect. of \$549K+ on a (3½) to (4) day Associate run week. **NEW**

SOUTHWEST RIVERSIDE COUNTY – (5) op comput. G.P. (4) ops eqt'd/5th plumbed. 2015 Project Gross Collect \$400K+. Cash/Ins/PPO. Located in a smaller prof. bldg. in a condo which can be purchased or leased. Seller giving up private pract. to accept institutional position. **NEW**

TUSTIN – (4) op comput. G.P. (3) eqt'd/4th plumbed. Located in a busy shop ctr. on a main thoroughfare. Exposure, visibility & signage. Digital x-rays & CEREC. Annual Gross Collect \$460K+ on an easy 4½ day week. Cash/Ins/PPO. No Denti-Cal or HMO. Growth potential. **NEW**

WEST SAN FERNANDO VALLEY – (4) op comput. G.P. w modern equipt. Located in a smaller prof. bldg. on a main thoroughfare. Cash/Ins/PPO pts. Annual Gross Collect \$750K+ on a (4) day week. Excell. long term lease, outstanding signage, & great off street parking. **SOLD**

UPCOMING PRACTICES: Bakersfield, Beverly Hills, Central Coast, Covina, Montebello, Oxnard, Pomona, San Gabriel, SFV, Temecula, Thousand Oaks, Torrance, Visalia & Valencia.

D&M SERVICES:

- Practice Sales and Appraisals
- Practice Search & Matching Services
- Practice and Equipment Financing
- Locate and Negotiate Dental Lease Space
- Expert Witness Court Testimony
- Medical/Dental Bldg. Sales & Leasing
- Pre - Death and Disability Planning
- Pre - Sale Planning

P.O. Box #6681, WOODLAND HILLS, CA. 91365

Toll Free 866.425.1877 Outside So. CA or 818.591.1401 www.dmppractice.com

Serving CA Since 1994 CA BRE Broker License # 01172430

CA Representative for the National Association of Practice Brokers (NAPB)



"Matching the Right Dentist
to the Right Practice"

Complete Evaluation of Dental Practices & All Aspects of Buying and Selling Transactions



Mike Carroll & Pamela Carroll-Gardiner

4043 SANTA ROSA GP

Well-established, well respected general dental practice located within a lovely professional center in the heart of town. Beautifully landscaped grounds with ample parking. Condo is also available for purchase. Owner/doctor works 3.5 days a week with 3.5 days of hygiene. Gross receipts average \$750-\$800K every year with an adjstd net of almost \$300K. Seller is willing to assist Buyer for a smooth transition. Asking price for practice only \$495K.

4076 MORGAN HILL GP

Absolutely beautiful and modern; established practice in well-known Professional Center. State-of-the-art office in approx. 1,000 sq. ft. 3 fully equipped ops, with room for a 4th op. 300+ active patients. Gross Receipts approx. \$245K. Ideal turn-key operation. Asking \$215K.

4075 PETALUMA GP

Established GP located in Petaluma in stunning 1,856 sq. ft. seller owned facility in class A, 2 story, 10 year-old professional building. State-of-the-art office includes 6 ops, staff lounge, reception area, private office, business office, lab area, sterilization area, consult room, separate storage area, bathroom plus private bathroom. 4 doctor-days & 4 hygiene days/wk. Avg. GR \$640K. Asking \$490K.

4068 MARIN COUNTY GP

Well established and respected, quality general practice located in desirable Marin County location. Office has convenient ample parking, overlooking a beautiful park like setting adjacent to a peaceful creek. Owner/Doctor is ready to transition into retirement. Office contains 5 ops in ~1,300 sq. ft. Gross receipts average \$1.2M annually with less than 4 doctor days/week. Adjusted net averaging ~\$400K for last 2 years. Doctor has experienced many gratifying years treating exemplary patients and requires an experienced G.P. with minimum of 2-5 years of experience.

4078 LOS ALTOS GP

Seller relocating and offering established 35 year old general practice in highly desirable area. 1,230 sq. ft. office with 3 fully equipped ops. 2014 GR \$500K+ Approx. 2 1/2 doctor-days. Asking \$350K.

4051 CENTRAL COAST PROSTHO

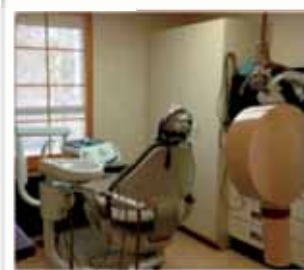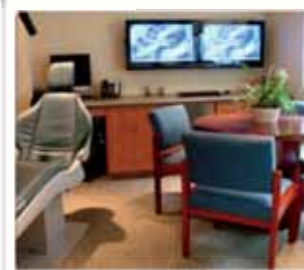Well-established practice located in California's gorgeous Central Coast area. Beautifully appointed, spacious 1,568 sq.ft. office with 4 fully equipped ops, pros lab and other amenities. Situated just minutes from the ocean and <5 miles away from one of California's historic Mission Cities, this practice is nestled in a highly desirable community. 2013 gross receipts were \$1.2M+ and 2014 is annualized at \$1.3M+ on a 4 day doctor workweek, w/4 days of hygiene/week. Approx. 15 new patients a month and ~1,500 active patients (all fee-for-service). Owner/doctor is willing to help Buyer for smooth transition.

4054 MID-PENINSULA ORTHO

This established orthodontic practice is located in desirable centrally located area with a solid economic base, numerous amenities & diverse residents. The ~~office~~ **SOLD** is state-of-the-art with 5 (open bay) ops in approximately 1,600 sq. ft. Both practice and building are for sale. Asking \$591K practice, \$937K building.

UPCOMING:

San Jose GP
Bay Area Perio



Carroll & Company
2055 Woodside Road, Ste 160
Redwood City, CA 94061

Phone:
650.362.7004
650.362.7005
650.362.7006

Email:
dental@carrollandco.info

Website:
www.carrollandco.info

CA DRE #00777682



WESTERN PRACTICE

800.641.4179

WPS@SUCCEED.NET
WESTERNPRACTICESALES.COM

What separates
us from other
brokerage firms?

Our extensive buyer
database and
unsurpassed exposure
allows us to offer you a

Better
Candidate

Better
Fit

Better
Price

We are a proud member of:



BAY AREA

AC-335 SAN FRANCISCO: Two great practices for the price of one! Call for Details!!

AC-417 SAN FRANCISCO Facility: Turn-Key Opportunity! 555 sf w/ 2 ops + 1 add'l. Call for Details!

AG-053: 3,000 sf w/ 9 ops + 1 add'l. PRIME LOCATION! \$595k

AG-402 SOUTH SAN FRANCISCO: Seller Highly Motivated! All New Upgrades! 1050 sf w/ 3 ops \$250k

AG-416 SAN CARLOS: Turn-Key located in a highly desirable community! 1,350 sf w/ 3 ops. \$90k

BN-183 HAYWARD: *Kick it up a notch by increasing the current very relaxed work schedule!* 1,300 sf w/ 3 ops \$150k

BN-279 CONTRA COSTA COUNTY: 2-story. 1,350 sf w/ 3 ops + 1 add'l \$60k

BC-361 OAKLAND: Established for over 23+ years! 2,200 sf w/ 7 ops. **Now Only: \$385k**

BC-381 PLEASANT HILL Facility: Open Floor Plan! 1,852 sf w/ 6 equipped ops! Move in Ready! \$80k

BG-407: SAN LEANDRO: Prof bldg. Great signage! 1200 sf w/ 3 ops \$150k

CC-390 SOLANO COUNTY: Near Travis AFB! Highly visible location! 950 sf w/ 3 ops \$200k

CG-366 SONOMA CO.: Vibrant, growing community! 1,300+ sf w/ 4 ops. Over \$760k in collections! \$480k

CN-344 N. SONOMA CO: Long-established, stellar reputation! 2560 sf, w/ 6 ops \$925k

CC-369 SAN RAFAEL: Perfect starter practice opportunity! 900 sf w/ 3 ops. \$350k

DC-370 SAN JOSE Facility: Available with or without patient charts! Move in Ready! Call for Details!

DG-351 PLEASANTON Facility: *Don't miss out! Reduced to sell quickly!* 1,000 sf w/ 3 ops. \$69k

DG-394 LOS GATOS: Highest Quality of Dentistry! Decades of Goodwill! 850 sf w/ 3 ops **ONLY \$280k**

DG-401 SAN MATEO: Fantastic El Camino Real Location. 900 sf w/ 3 ops \$125k

DG-341 SUNNYVALE/LOS GATOS Combined Sale: Contact our office for details. \$605k

DG-396 SERRAMONTE AREA: Small Town Feel in Heart of SF. 850 sf & 4 ops \$485k

DN-311 PLEASANTON Facility: Great Location! 870 sf w/ 3 ops + 1 add'l. **NOW ONLY: \$75k**

DG-413 CUPERTINO: Rare Opportunity near APPLE "Spaceship" Campus! \$1.15m

DN-312 LIVERMORE Facility: Don't miss out on this one! 1,070 sf w/ 3 ops. **REDUCED! \$75k**

DN-353 ALAMEDA: Fantastic Opportunity with view of the estuary 2,060 sf w/ 5 ops. **Now Only: \$750k**

DN-388 WATSONVILLE 2,393 sf w/ 4 ops + 4 add'l. **Must Sell Quickly! All Reasonable Offers Considered!**

DC-403 SANTA CRUZ: Well-established, modern, quality practice! 1,335 sf w/ 4ops. \$725k

BAY AREA CONTINUED

DN-409 SAN JOSE Facility: Desirable neighborhood w/ fantastic visibility! 1,400 sf w/ 7 ops. \$95k

DN-408 SAN JOSE: Seller is retiring and is passing this onto you! 1,300 sf w/ 2 ops + 2 add'l. \$75k

DC-419 NEWARK Facility: Location, Location, Location! 1,400 sf w/ 4 op. \$140k

NORTHERN CALIFORNIA

EN-340 SACRAMENTO: Large HMO practice! 3,400 sf w/ 10 ops and Plumbed for 1 add'l \$950k

EN-350 SACRAMENTO: The Perfect Merger Opportunity! Old-fashioned values and philosophy! 674 sf w/ 1 op. \$85k

EN-378 LINCOLN: quality practice with a wonderful patient base! 1,369 sf w/ 2 op + 3 add'l. \$170k

EN-379 ROSEVILLE: An amazing opportunity in the location of your dreams! 1,040 sf w/ 3ops. \$295k

EN-391 SACRAMENTO: Opportunities like this one are "few and far between"! 1,200 sf w/ 4ops. \$310k

EN-423 FOLSOM Oral Surgery Facility: Primed for success! 3,450 sf w/ 2 Lrg. Treatment Rooms. \$100k

FN-181 NORTH COAST: Well respected FFS GP. Stable patient base. 1,000 sf w/3 ops \$150k (25% int. in bldg. avail.)

FN-299 FERNDALE: Live and practice on the beautiful North Coast! 1,300 sf w/ 3 ops \$225k (Real Estate: \$309k)

FC-334 NORTHERN CA: Emphasis on prevention. 1,200 sf w/ 4 ops \$480k / Real Estate Also Available!

FC-343 NORTHERN CA: Quality & location are the keys to success! 1,200 sf w/ 3 ops + 1 add'l & 1 hyg. Op. \$500k (Real Estate \$375k)

GG-320 CHICO: Large, Unique, Originally designed for more than 1 dds! 5,000 sf w/ 7 ops (+2 add'l) \$985k

GG-386 REDDING: Practice & Real Estate! 2,860 sf w/ 4 ops. Plumbed for 2 add'l! \$360k and \$660k

GN-201 CHICO: Beautiful practice, major thoroughfare, stellar reputation! 1,400 sf w/ 4 ops & room for another \$425k

GN-244 OROVILLE: Gorgeous, Spacious. 2,500 sf w/5 ops! Collections over \$450k in 2013. \$315k

GN-258 REDDING: Pristine and attractive! Conveniently located! 1,050 sf w/ 2 ops. \$215k

GN-387 CHICO: Streamlined overhead and reasonable rent. 1,000 sf w/ 3 ops. \$235k

GN-399 REDDING: Loyal patient base and relaxed workweek schedule. 1,440 sf w/3 ops. \$150k

GN-404 SHASTA AREA: A fantastic place to live, work and raise a family! 1,500 sf w/3 ops \$100k

GN-418 REDDING: Goodwill Galore! Established for ~37 years and the seller is retiring! 3,200 sf w/6 ops +2 add'l. \$495k

SALES

NORTHERN CALIFORNIA CONTINUED

HG-298 REDDING FOOTHILLS: HEALTH FORCES SALE! Includes Cerec! 2,000 sf w/ 5 ops **Practice \$100k / Real Estate \$250k**

HN-213 ALTURAS: FFS practice is 2,200 sf w/ 3ops +1 add'l **\$115k**

HN-280 NORTHEASTERN CA: "Only Practice in Town" 900 sf w/ 2 ops **\$110k**

HN-290 PLACERVILLE: Excellent Merger Op! Embrace the lifestyle and build your success story here! FFS. 1,400 sf w/ 4 ops **\$210k**

CENTRAL VALLEY

IG-067 STOCKTON: Fully computerized, paperless, digital. 5,000 sf w/10 ops **Steal of the Century! Now ONLY \$240k**

IG-367 MERCED: Newly Remodeled, Paperless. 1,550 sf w/4 ops **REDUCED! \$325k**

IN-297 MODESTO: Pristine, contemporarily designed medical/prof ctr. 1,980 sf w/ 4 ops. **PR: \$475k / RE: \$425k**

IN-345 MODESTO: Long-standing tradition of quality care. 3016 sf w/ 5ops + 1 add'l. **\$495k**

IN-358 MODESTO: Practice nets over 50%! 1,200 sf, 3 ops+1 add'l. **\$350k**

IN-397 FRESNO/MADERA: "the Perfect Location"! 2,000 sf w/5ops. **\$480k**

JN-295 VISALIA: Practice & Real Estate 2,000 sf w/ 5 ops **PR: \$185k RE: \$300k**

JC-349 FRESNO: Well Respected Specialty Practice limited to Dental Sleep Medicine. **Call for Details!**

JG-400 CLOVIS: Best priced practice on the market! Digital Pano, Cerec and \$330k in PROFIT annually! **\$465k**

SPECIALTY PRACTICES

I-7861 CENTRAL VALLEY Ortho: 2,000 sf, open bay w/ 8 chairs. Fee-for-Service. **\$370k**

I-9461 CENTRAL VALLEY Ortho: 1,650 sf w/5 chairs/bays & plumbed for 2 add'l **\$180k**

DG-264 SAN JOSE Ortho: \$300-400k in build-outs alone! 1800 sf w/ 5 chairs. **REDUCED! \$245k**

AC-325 SF Endo: TDO. Dexis. Central nitrous. 555 sf w/ 2 ops. **\$250k**

BC-336 CONTRA COSTA CO Perio: 1,440sf, 4 ops +1 Great Location! **Call for Details!**

CC-346 SO MARIN CO Perio: 1,142 sf w/ 3 ops. Meticulously maintained! **REDUCED! \$199k**

BN-393 PINOLE Pedito: Streamlined practice, where every child counts themselves lucky to be a patient here! 2,000 sf w/ 5 ops. **\$1.2m**

ASK THE BROKER



Timothy G. Giroux, DDS is currently the Owner & Broker at Western Practice Sales and a member of the nationally recognized dental organization, ADS Transitions.

You may contact **Dr Giroux** at: wps@succeed.net or 800.641.4179

How important is the active patient count?

Recently this number has become a totally over-blown issue. It is simply one of many metrics that a dentist can use to determine if the treatment philosophies are similar. The due diligence process should be used to answer the most important question a buyer can ask: ***What can I expect to produce/collect on this particular patient base?*** Looking at the types of procedures, the number of prophys, the type of recall system AND a patient count should help answer that question.

As dentists, we do not even have a definition for an "active patient". Generally, most of us in the transition business have accepted the definition to mean any patient that has been in the office for at least one visit in the past two years. Arguably that might not include the terrific patients that definitely get their major treatment performed but may only show up every three years, or when something breaks. It also counts the patients that are one-timers only who may not come back. ***I have never seen a situation where the Seller truly believed he had less patients than what the Buyer counted!***

Every buyer is strongly encouraged to do their own chart count to make sure they can duplicate the production on that particular patient base. Essentially their perceived number of patients is irrelevant to market price and is really only relevant as it relates to them duplicating the production. This conclusion may sound strange, but it is the reality of practice sales. Only the buyer can determine if a particular practice is a good fit.

In my seminars, we could present a patient case and ask for 10 dentists to give a treatment plan. We would probably have 10 different treatment plans, with some possibly advising eventual full mouth reconstruction and others advising few restorative needs, while watching the remaining teeth. I can also tell you that every dentist believes that they are "just right" when it comes to their own treatment plans. Therefore, I could place those 10 dentists in a practice purchase and I might get two failures, two wildly successful outcomes and six dentists that finish within 15% of the original practice collections. **ALL WITH THE SAME PATIENT BASE!** The Practice Price is NOT based on the number of patients. It is based on the collections and profitability!

Every patient base is unique based on their needs and their ability to pay. The number of patients may not be as important as the type of patients.



Jon B. Noble, MBA




Mona Chang, DDS



John M. Cahill, MBA



Edmond P. Cahill, JD



A look into the latest dental and general technology on the market

Adobe Fill & Sign (Adobe, Free)

Adobe Fill & Sign is a powerful app that takes digital documents and gives users the ability to fill and sign them easily without the need to print them. After completing an optional profile and signature information, users can import PDF forms or photos of forms into the app. PDF forms can come from the Web or from other apps. Photos of forms can come from the camera roll or a picture taken right from the device. When a form is loaded, users simply tap on an area and start typing to fill out the form. Annotations such as check boxes or bubbles can be made by a tap-and-hold gesture. Signatures or initials can be added to the form by simply selecting an area and tapping on the pen. Quick tools that appear when tapping an area make it easy to edit and delete anything previously added. Areas can be automatically filled by selecting information from the optional profile and signature entries. Completed forms can be printed, messaged, emailed or shared with virtually any app. Users with an Adobe ID have the ability to store forms in the cloud.

— Hubert Chan, DDS

Periscope (Twitter, Free)

Periscope for Twitter is a social media app that takes on live-streaming video and makes it easy to use in the process. Periscope requires a free account using Twitter credentials. Once an account is created, users will find Periscope familiar because of its similarity to Twitter. Users can choose to follow anyone with a Periscope account. Live activity feeds of followed users as well as a public feed can be viewed through the app. Notifications of followed users when they broadcast are available. Users specify titles of their broadcasts and whether the videos can be shared publicly or privately to select accounts. Instantly, the broadcast title appears in the live activity feed timeline as well as notifications sent to those following the account. Periscope users who select the broadcast see the live video. Users joining the broadcast appear as notifications on the video and can comment. Likes are recorded by users in the form of floating hearts that appear by tapping on the screen. The total number of users watching the broadcast at any one time is displayed. Trending broadcasts are prominently displayed in the public live activity feed.

— Hubert Chan, DDS

Myldol (Huanshi Ltd., Free)

You may have seen the life-like cartoon character images of your friends on Facebook, with their face supplanted on a comic book version of themselves. Most likely, this came from a Chinese app that has sent the Internet into a frenzy. Myldol allows users to scan a photo of themselves and the app automatically designs an eerily similar cartoon replica. Users can then select skin tone, hairstyle, clothing and more to make themselves more lifelike. The app takes it to a comedic level when users can insert their character into unusual singing, dancing and action scenes, which are synced with music. Humorous photos/emojis also can be created. As a caution to potential users, note that the app's language is set to Chinese. This can make the navigation difficult, but anyone savvy enough with how apps operate can figure it out.

— Blake Ellington, Tech Trends Editor

Technology Becoming Key Part of Construction

Technology has made its way into wearable items and cars, but now it is becoming a primary selling point for home builders. According to the Consumer Electronics Association (CEA), technology incorporation is a necessity these days in home construction. CEA conducted a study that found eight in 10 builders now offer clients features like structured wiring (84 percent), home theater (80 percent) and monitored security systems (80 percent), according to a CEA statement. The study also found that broadband Internet is now a standard feature in homes, as nine in 10 new homes are equipped with broadband cable — up from 69 percent in 2008, according to CEA. Shipment revenues in the U.S. consumer electronics market are expected to reach \$223.2 billion in 2015 — a 3 percent increase from 2014, according to CEA's U.S. Consumer Electronics Sales and Forecast.

— Blake Ellington, Tech Trends Editor

Would you like to write about new technology?

Dentists interested in contributing to this section should contact Tech Trends Editor Blake Ellington at blake.ellington@cda.org.



Your convention. Your insider access.

Get a first look at practice-changing programs, lectures and hands-on workshops at *CDA Presents*. Homayon Asadi, DMD, along with dozens of other world-class speakers and innovators in every facet of dentistry, will be sharing knowledge and ideas with you. *CDA Presents The Art and Science of Dentistry*. Yeah, this is your convention.

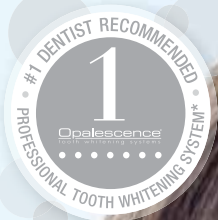Thurs.–Sat.
August 20–22
2015

Moscone
South
San Francisco

Register today
cdapresents.com

cda
PRESENTS

The Art
and Science
of Dentistry



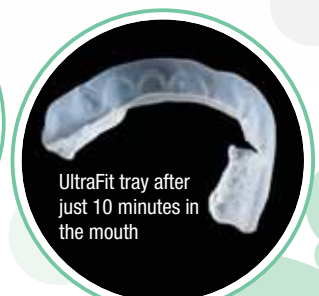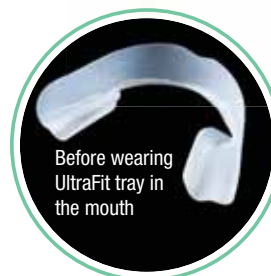Opalescence
go

FAST
EASY
EFFECTIVE



FOR A BRIGHT,
WHITE SMILE!

With no impressions or custom trays necessary, Opalescence Go is a professional tooth whitening system that is ready to use right out of the package! The comfortable, adaptable UltraFit prefilled tray gives molar-to-molar coverage and keeps the gel in place.



800.552.5512 | ultradent.com

© 2015 Ultradent Products, Inc. All Rights Reserved.

* Based on global sales data.

ULTRADENT
PRODUCTS, INC.